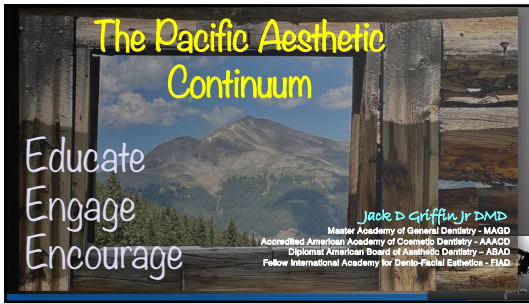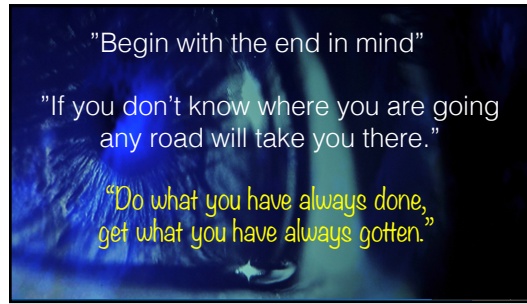

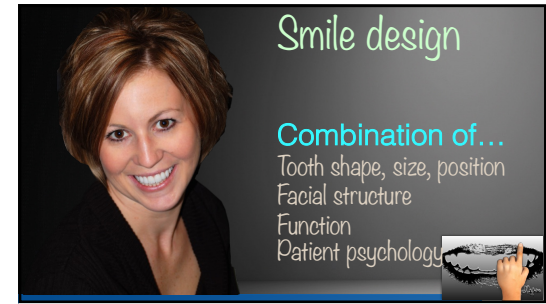
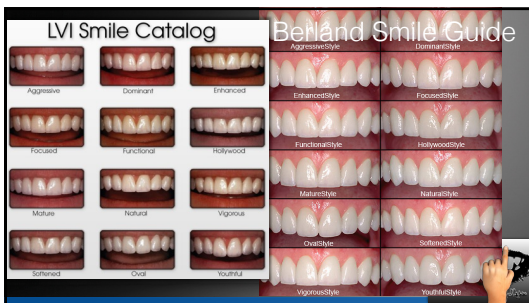1



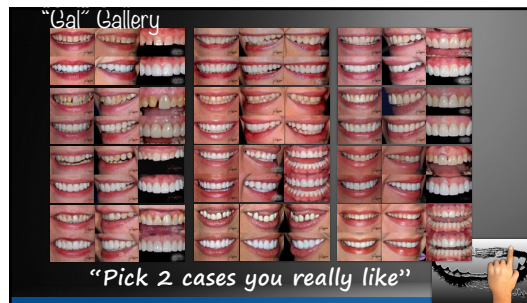2



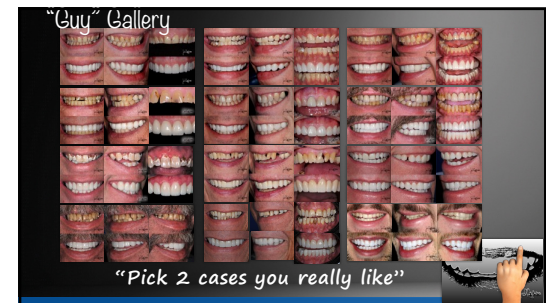3



4



5



6

**Global Aesthetics**  
Relation of smile to the face

**Macro Aesthetics**  
Shape, contour, and position of teeth and soft tissue

**Micro Aesthetics**  
Characteristics of teeth: shape, shade, color, translucency

AACD American Academy of Cosmetic Dentistry

7

### Smile line

- ✓ The line along maxillary incisal edges
- ✓ Should mimic superior border of lower lip
- ✓ "Reverse Smile" is when centrals are much shorter than cuspids on this line
- ✓ Facial asymmetry and photography can throw you off
- ✓ "Lip Line" is inferior border of upper lip

Global Aesthetics

8

### Facial planes

- ✓ "Incisal Plane" is the horizontal plane along the maxillary incisal edges
- ✓ "Occlusal Plane" is a line connecting incisal edges of anterior teeth and the occlusal surfaces of the posterior teeth
- ✓ "Midline" is the vertical line between the contact of the maxillary central incisors

Global Aesthetics

9

### Midline

- ✓ Maxillary midline should line up with center of face
- ✓ Should be parallel to long axis of face
- ✓ Often at right angles to the incisal plane
- ✓ May be aesthetically acceptable if within 4mm of long axis of face
- ✓ A cant of 3 or more degrees is **unacceptable**

Global Aesthetics

10

### Incisal edge position

- ✓ "EP" = cornerstone on which all smile design is initiated
- ✓ At rest 2-4 mm should show in young to middle age female
- ✓ Functional and aesthetic parameters make this somewhat unique on all patients
- ✓ Should fall within **smile line** of lower lip at close

Global Aesthetics

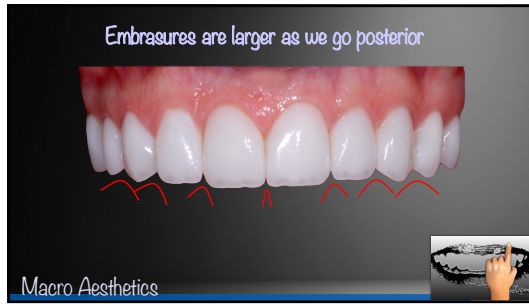11

### Factors determining "acceptable" smile:

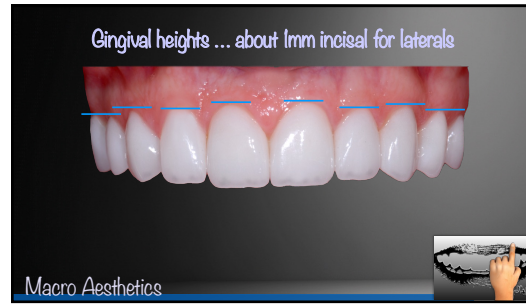- Embrasures
- Gingival heights
- Axial inclination
- Contacts
- Width-height ratio
- Central dominance
- Teeth proportionality

Macro Aesthetics

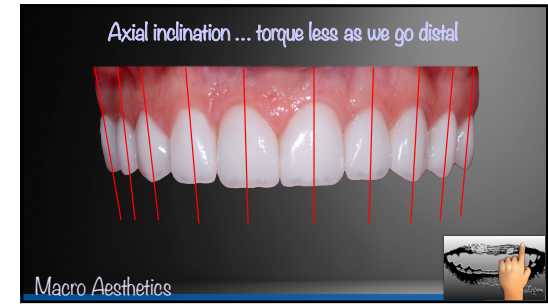12



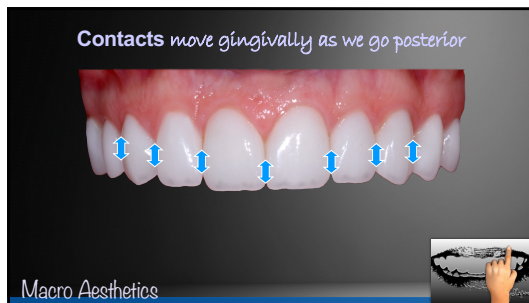13



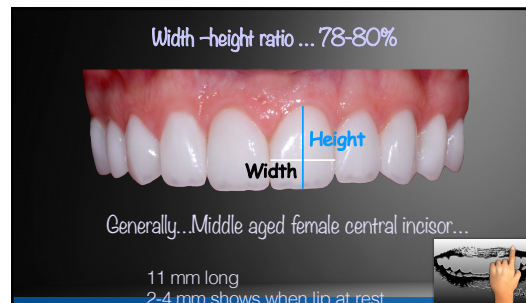14



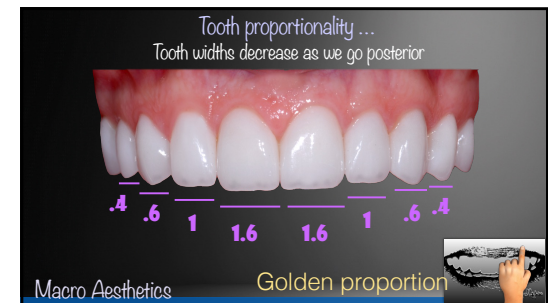15



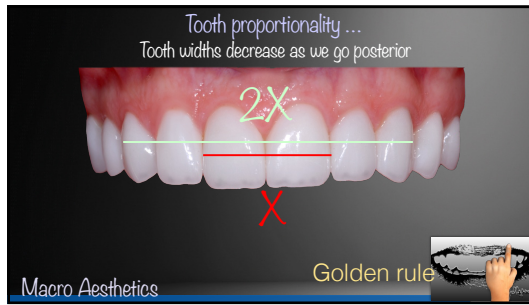16



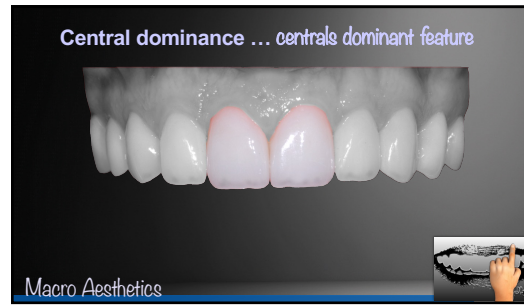17



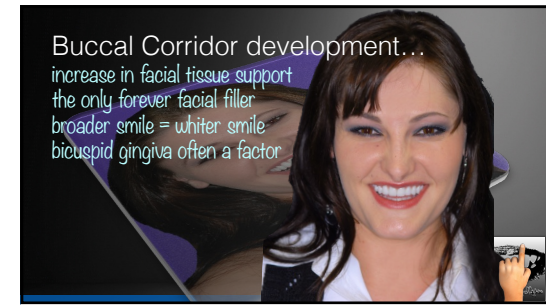18



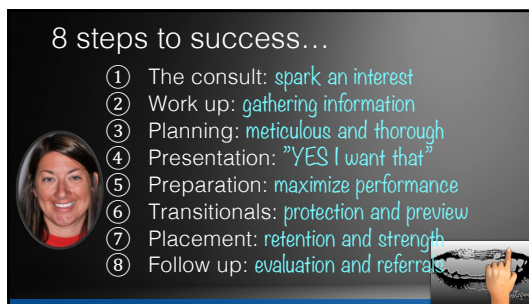
19



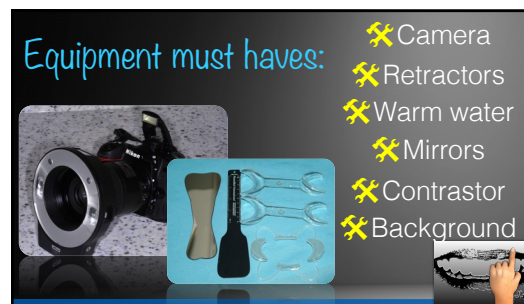20



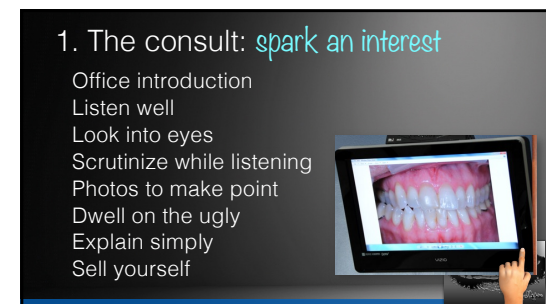21



22





23



24

2. Work up: *gathering information*


- Full photo series
- Impressions
- Bite registration
- Pre-op shade
- Radiographs
- Perio evaluation
- Disease correction plan

25

3. Planning: *meticulous and thorough*

- Centered around pt desires
- Temper with physical reality
- Aim for long term success
- Experience matters
- Undistracted planning
- Don't be afraid to ask – doctor, lab, etc



26

4. Presentation: *YES I want that*

- No distractions
- Show them
- Explain simply
- Give choices
- Educate
- Sell yourself
- Front office involvement




27

5. Preparation: *maximize performance*

- Know where you are going
- Understand materials
- Understand your patient
- When in doubt, conserve
- Pace yourself
- Constant self evaluation
- Learn to enjoy




28

6. Transitionals: *protection and preview*

- Patient preview of length and color
- Emphasize importance to patient
- Follow up at 3-5 days
- Communicate changes with lab




29


7. Placement: *retention and strength*

- Meticulous
- Understand materials
- Know a few well
- Plan in advance
- RELAX





30

### 8. Follow up: *evaluation and referrals*




- Follow up appointments
- Listen to patient
- Document concerns
- Follow with photos
- Analyze you and lab
- Adjust for future
- Add to portfolio



31

### How do you know when to stop drill'n?

- ☺ The minimum amount to insure an excellent result
- ☺ Bond to enamel is best long term bo
- ☺ Remove decay & failing restorations
- ☺ Shallower usually less sensitivity
- ☺ More remaining tooth structure, more restorative options later



32

### "Anti-Reduction" guide



- E\_max
- Finish diamond
- Smooth
- Rounded
- Reduction guide



33

### Before Temps



- Impressions
- Bite registration
- Kois Analyzer
- Prep shades
- Photos





34

### 3 potential sources of iron...

1. Blood (hemoglobin)
2. Hemostatic agents (ferric oxide)
3. Bacteria (leakage)

🗑️👉 Iron oxides = rust = black scuz = failure






35

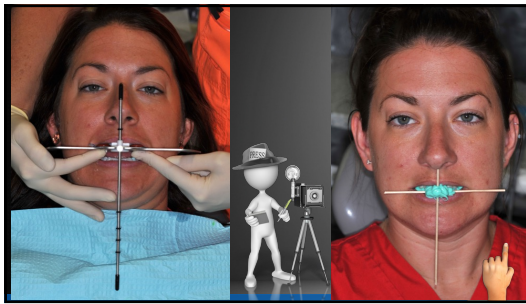
### Kois Dento-Facial Analyzer

#### Panodent

- Patient supine
- Plastic tab touches facial of central incisors
- Sit patient up to verify
- Use assistant to inspect
- Eyes are often not parallel
- Reheat and smush tabs to re-do
- Take photo when correct
- Only send in plastic tray (no metal to lab)

36



37

### Li2 veneer

- 0.3-0.5 mm margin
- Rounded shoulder or chamfer
- No sharp internal line angles
- No incisal "wrapping"
- Maintain facial curvature
- Smooth prep
- Bond to enamel best

38

### Li2 layered Crown

- 1.0-1.5 mm margin
- 1.5-2mm oocl clearance
- Rounded shoulder or chamfer
- 4-8 degrees taper
- 3-4mm axial wall height
- No sharp internal line angles
- Smooth prep
- Bond to enamel best

39

### Diode laser

- ❌ Valuable asset ... if the perio is bad the case is a failure
- ❌ Fairly inexpensive ... \$1500-\$3500
- ❌ Predictable ... no surprise healing
- ❌ Versatile ... gingivoplasty, frenctomy, troughing, perio tx, implant exposure, etc

40

Keep restoration margin 2.5-3mm from boney crest to avoid problems

**Dentogingival complex =**  
sulcus depth +  
epithelial attachment +  
connective tissue attachment

**Biologic width =**  
epithelial attachment +  
connective tissue attachment

41

### Cementation Sanity

The most durable aesthetic restorations  
**EVER**  
(and how to stick 'em in)


42

3 most popular indirect materials used most today:

**Lithium Disilicate** – Silica based ceramic, **treat as porcelain**

**Zirconia** – Non-silica metalo-ceramic, **treat as metal**  
 Posterior Zirconia: more strength and more opaque  
 Anterior Zirconia: less strength and less opaque

Goals  
 1. Durable  
 2. Esthetic  
 3. Comfortable




43

**Durable aesthetic restorations:**

**Lithium Disilicate (IPS e.max)**  
 Particle Filled Silica Glass  
 360-400 MPa flexural strength  
 Adhesive cementation best  
 Strong enough to handle cementation  
 Traditional porcelain bonding

**Zirconium Oxide (Bruzir, Lava...)**  
 Polycrystalline metallic type  
 1000 MPa flexural strength  
 NO silica so not etchable  
 Cement or bond in place



44



Zirconia

Lithium disilicate

Goals  
 1. Durable  
 2. Esthetic  
 3. Comfortable



45

Over 70% of full coverage restorations are zirconia

3 basic groups of restorative zirconia:  
 Anterior Zirconia  
 Posterior Zirconia  
 Blended Zirconia




46

**Zirconia**

**Good prep: Almost anything works**  
 Cements – Regenerative cement, RMGI (Ceramir, RelyX Luting, FujiCem...)  
 Self Adhesive Dual Cure Resin – (TheraCem, BeautiCem, SmartCem, UniCem, BIFix...)  
 Adhesive = Universal DBA + dual cure resin (All Bond U+DuoLink, MultiLink, ScotchBond U+Ultimate...)

**Less than ideal prep Need adhesion**  
 Self Adhesive Dual Cure Resin OR  
 Adhesive = Universal DBA + dual cure resin




47

Everyday excellence

**Zirconia:** “Ideal” prep AND low occlusal stress


Try in Restoration  
 Clean – cleaner  
 Rinse  
 Dry  
 Tooth  
 Isolate  
 Clean – 2X2 gauze  
 Cement – almost anything will work  
 Self adhesive therapeutic dual cure resin



48

**Maximum performance**  
**Zirconia:** "Compromised" prep OR high occlusal stress


- Try in
- Restoration
  - Cleaner
  - Rinse
  - Dry
- Tooth
  - Isolate
  - Clean – pumice, chlorhexidine
  - Universal DBA
- Cement
  - Adhesive dual cure resin



49

**Zirconia cementation science:**

1. If **prep good**, almost any cement works
2. Self-adhesive resin cements with **10-MDP** had significantly more success than traditional cements (i.e. Zinc Phosphate, RMGI)
3. Poor retention preps and/or high occlusal stress, adhesion with resin-bonding is required and **NOT AN OPTION** for clinical success
4. Proper resin bonding is more critical for high translucency ZR success
5. 50 micron Al<sub>2</sub>O<sub>3</sub> air abrasion or a cleaner to **remove phosphates** before adhesive cementation makes a significant difference with adhesion




50

**Lithium disilicate**  
 HFI etch + silane then try in

**Good prep: Dual cure resin significantly better than cement**  
 Self Adhesive Dual Cure Resin –  
 (TheraCem, BeautiCem, SmartCem, UniCem, BiFix...)  
 Adhesive = Universal DBA + dual cure resin  
 (All Bond U+DuoLink, MultiLink, ScotchBond U+Ultimate...)


**Less than ideal prep Need adhesion**  
 Self Adhesive Dual Cure Resin with DBA  
 OR  
 Adhesive = Universal DBA + dual cure resin



51

**Everyday excellence**  
**Lithium disilicate:** "Ideal" prep AND low occlusal stress


- Try in
- Restoration
  - Clean – cleaner (ZirClean Bisco, Ivoclean Ivoclar, Microetcher Danville)
  - Rinse
  - Dry
  - Reapply silane
- Tooth
  - Isolate
  - Clean – 2X2 gauze
- Cement – almost anything will work
  - Self adhesive dual cure resin (TheraCem Bisco, Activa Ivoclar, UniCem 3M)



52

**Maximum performance**  
**Lithium Disilicate:** "Compromised" prep OR high occlusal stress

- Try in
- Restoration
  - Clean – cleaner (ZirClean Bisco, Ivoclean Ivoclar, Microetcher Danville)
  - Rinse
  - Dry
- Tooth
  - Isolate
  - Clean – pumice, chlorhexidine
  - Dual cure Universal DBA (All Bond U Bisco, Scotchbond U 3M)
- Cement
  - Self adhesive dual cure resin cement (SpeedCem, UniCem 3M)
  - OR--- Adhesive dual cure resin (DuoLink Bisco, Ultimate 3M)




53

**Cement**      **Bond**

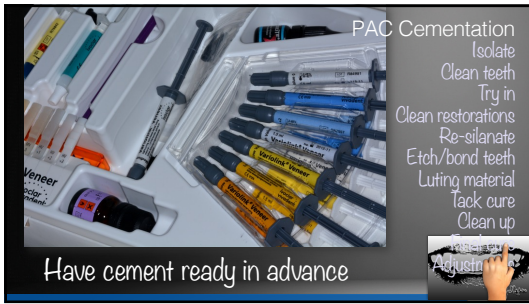**Cement for:**  
 regeneration  
 easy clean up  
 efficiency

**Bond for:**  
 more retention  
 stronger porcelain  
 better aesthetics

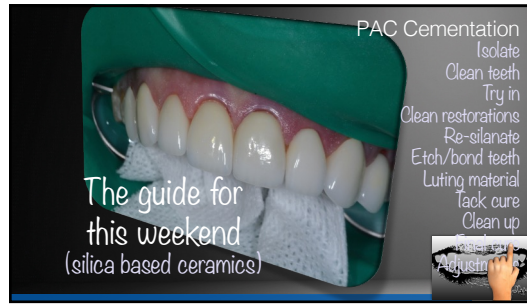Emax – 95% bonding agent + resin cemen  
 Zirconia – 95% self adhesive resin cemen



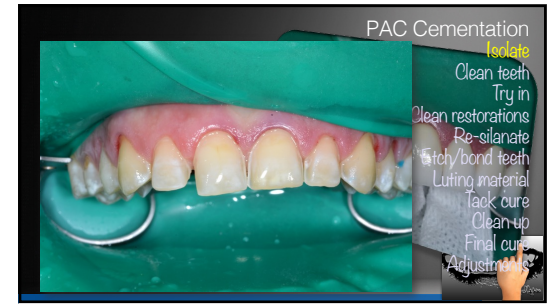54



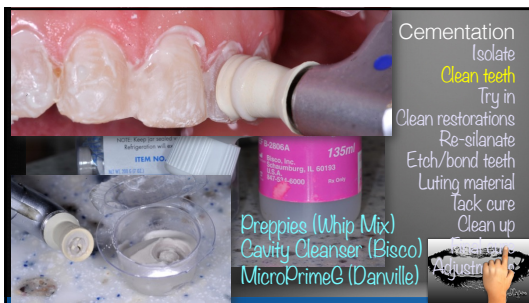55



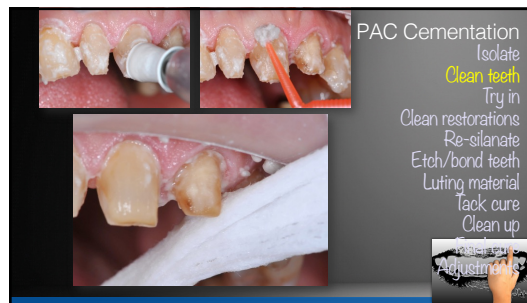56



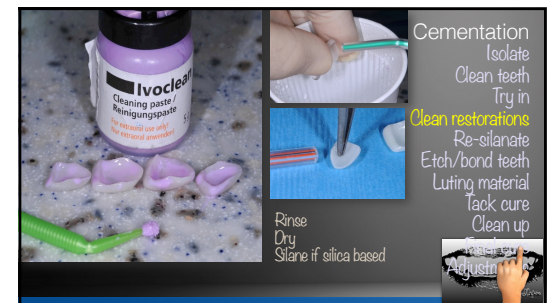
57



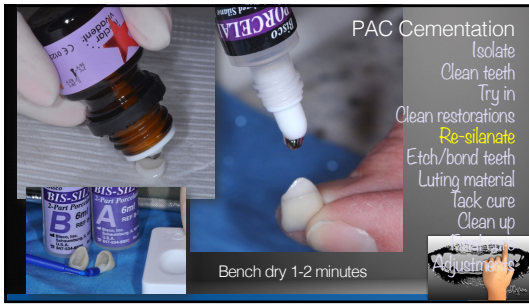58



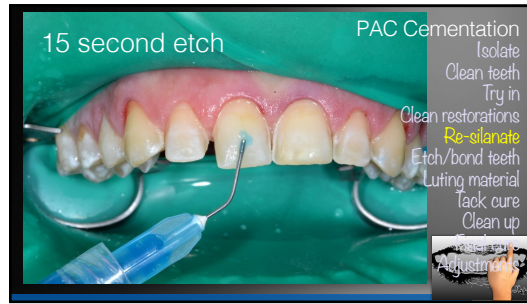59



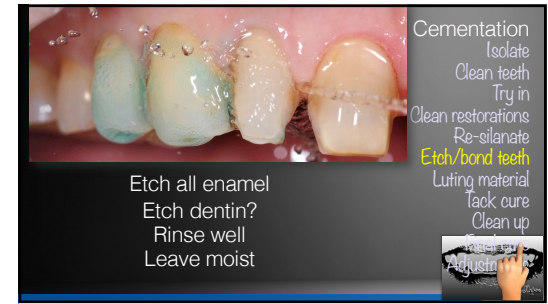
60



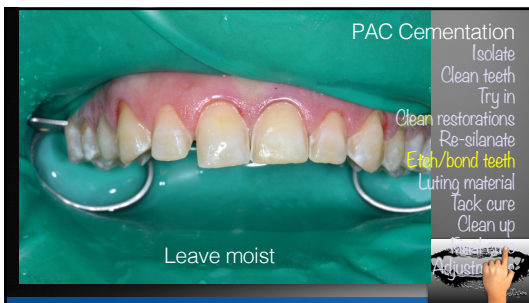
61



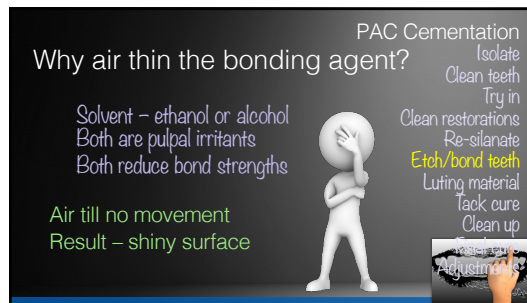
62



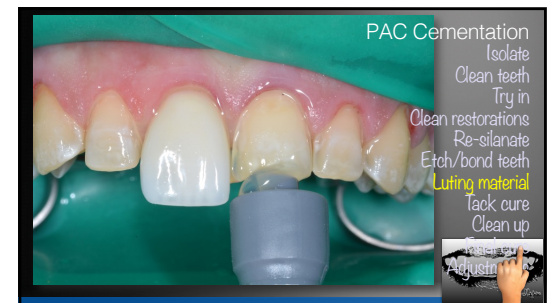63



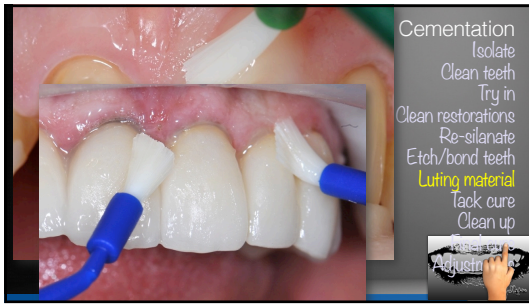64



65



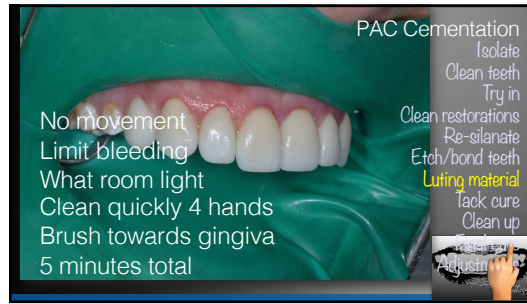66



Cementation  
 Isolate  
 Clean teeth  
 Try in  
 Clean restorations  
 Re-silicate  
 Etch/bond teeth  
 Luting material  
 Tack cure  
 Clean up



67

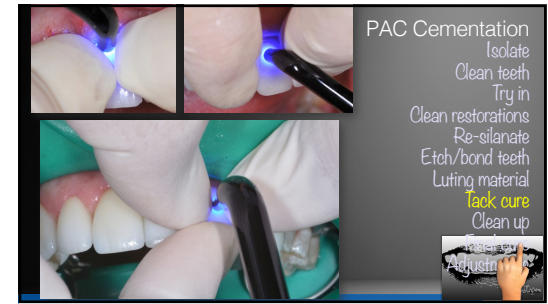


PAC Cementation  
 Isolate  
 Clean teeth  
 Try in  
 Clean restorations  
 Re-silicate  
 Etch/bond teeth  
 Luting material  
 Tack cure  
 Clean up

No movement  
 Limit bleeding  
 What room light  
 Clean quickly 4 hands  
 Brush towards gingiva  
 5 minutes total



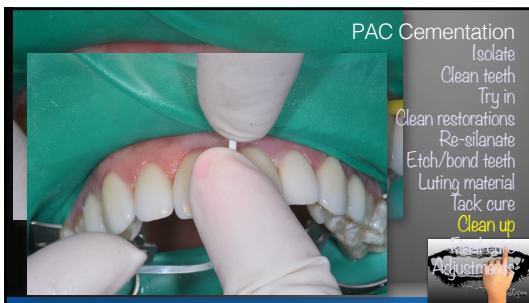68



PAC Cementation  
 Isolate  
 Clean teeth  
 Try in  
 Clean restorations  
 Re-silicate  
 Etch/bond teeth  
 Luting material  
 Tack cure  
 Clean up



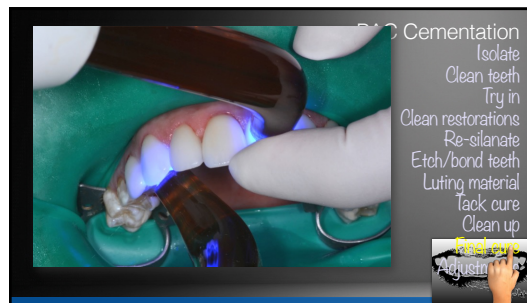
69



PAC Cementation  
 Isolate  
 Clean teeth  
 Try in  
 Clean restorations  
 Re-silicate  
 Etch/bond teeth  
 Luting material  
 Tack cure  
 Clean up



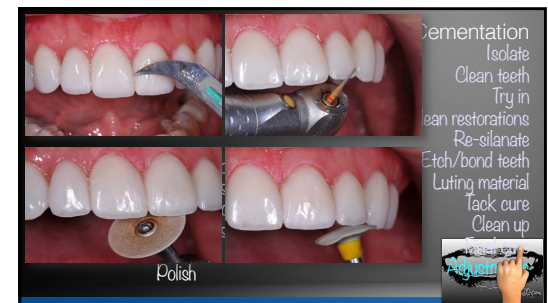70



PAC Cementation  
 Isolate  
 Clean teeth  
 Try in  
 Clean restorations  
 Re-silicate  
 Etch/bond teeth  
 Luting material  
 Tack cure  
 Clean up



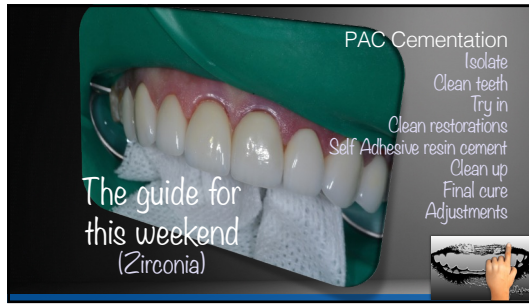71




Cementation  
 Isolate  
 Clean teeth  
 Try in  
 Clean restorations  
 Re-silicate  
 Etch/bond teeth  
 Luting material  
 Tack cure  
 Clean up



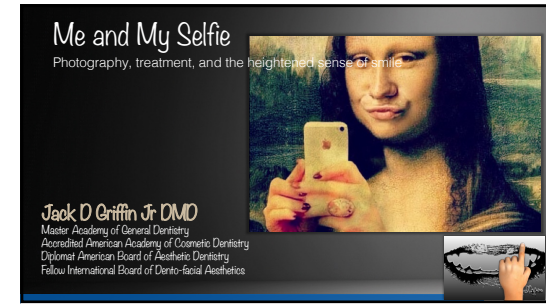72



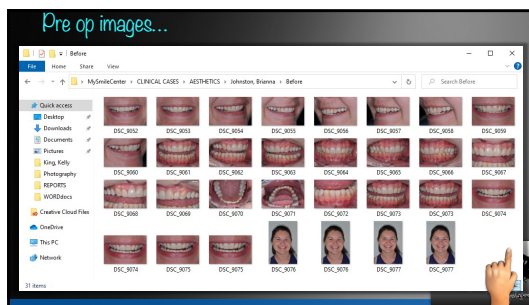
73



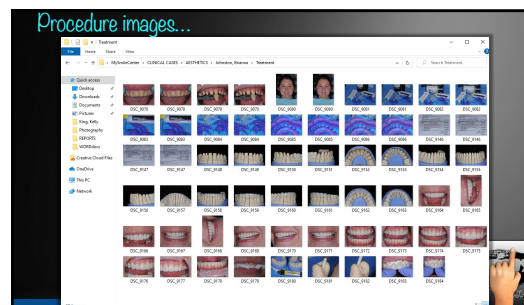
74



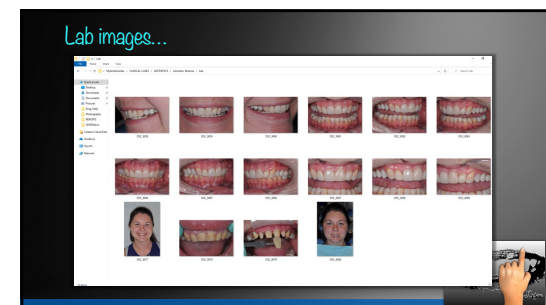
75



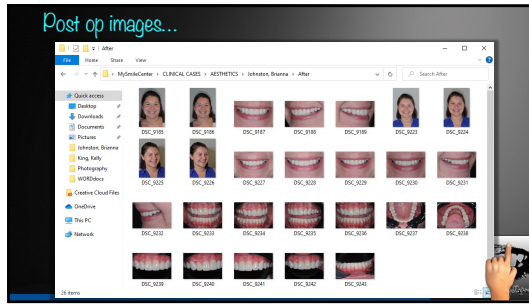
76



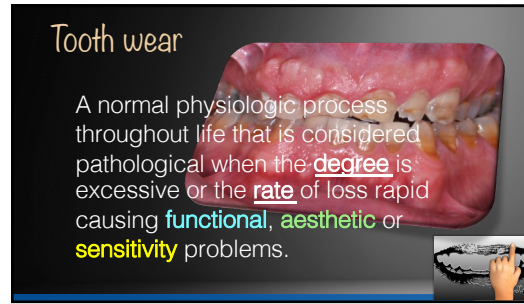
77



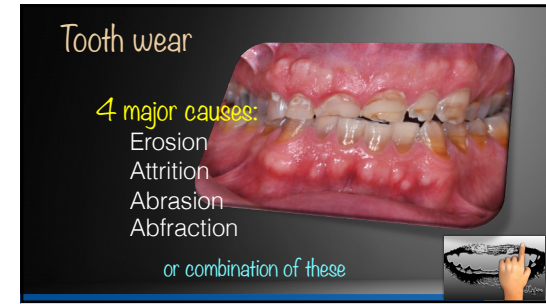78



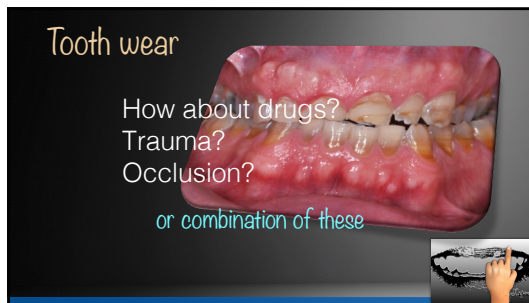
79



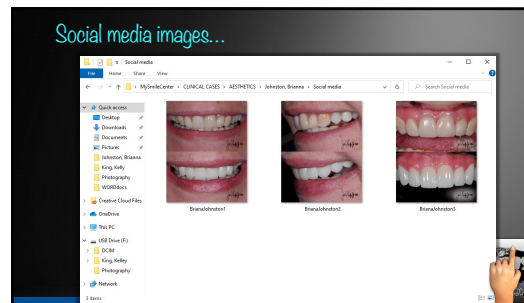
80



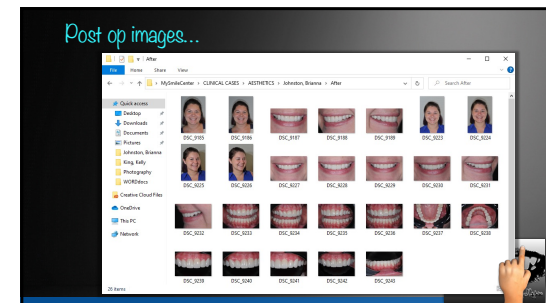
81



82



83



84