

Maintaining Natural Tooth Proportions in the Cosmetic Bonding of Misshapen Adolescent Teeth

Direct resin veneers enable the clinician to express his or her artistic skills chairside. This restorative modality depends on one's ability to **achieve proper contours, shade, and tooth proportions.**

The use of composite resins with varying **translucency and polishability** is required when closing spaces, changing tooth size, and creating natural tooth nuances and character.

Use of proportion guides

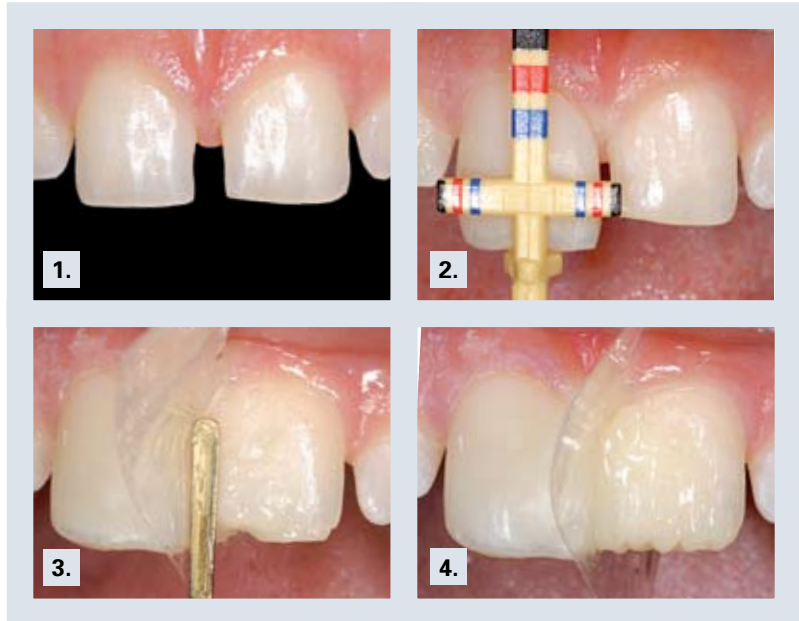
(Chu's Aesthetic Gauges, Hu-Friedy, Chicago, IL), anatomical matrices, and photographic evaluation can make resin placement much more efficient.



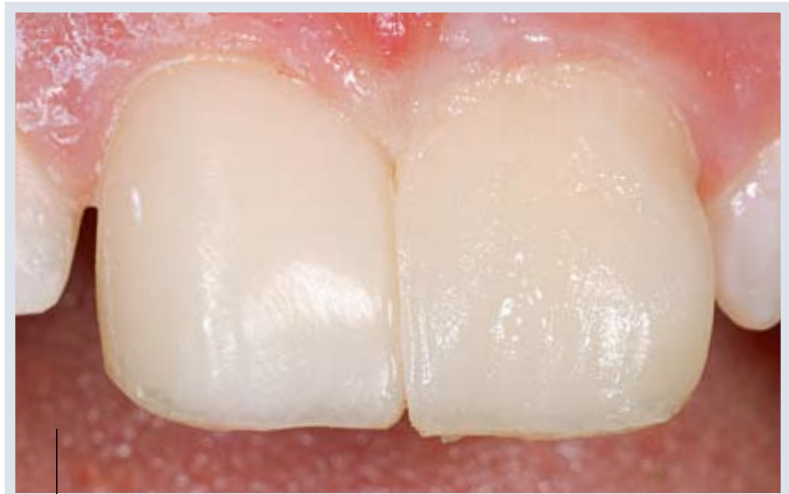**Jack D. Griffin, Jr.,
DMD***

*Private practice, Eureka,
Missouri.

18 Hilltop Village Center Drive
Eureka, MO 63025
Tel : 636-938-4141
E-mail: esmilecenter@aol.com

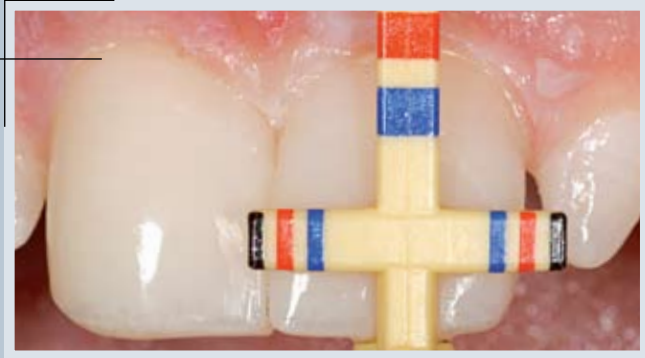


1. Teeth were in less than ideal positions, and a direct composite technique was selected for smile enhancement.
2. Using a proportion guide (Chu's Aesthetic Gauges, Hu-Friedy, Chicago, IL), a height-to-width ratio of 78% was achieved.
3. A microhybrid composite was placed and held using a mylar strip placed into the sulcus to complete diastema closure.
4. An incisal-shaded composite material was then used to create the incisal edge.

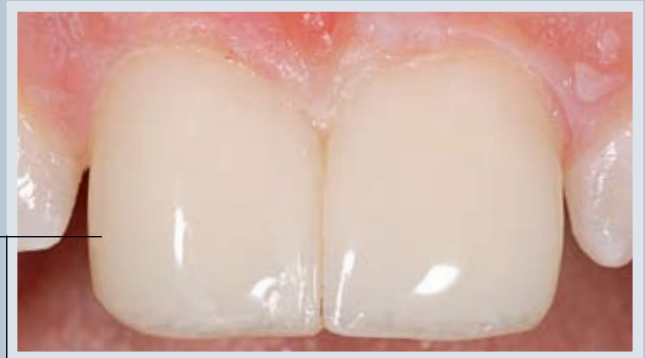

5. The matrix was removed once sufficient interproximal contacts were developed to allow for finalization of the restoration.

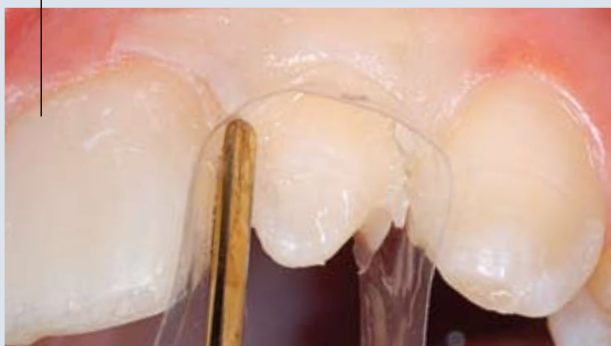6. Aesthetic gauges (Chu's Aesthetic Gauges, Hu-Friedy Inc, Chicago, IL) were used to verify proper height-to-width proportions.



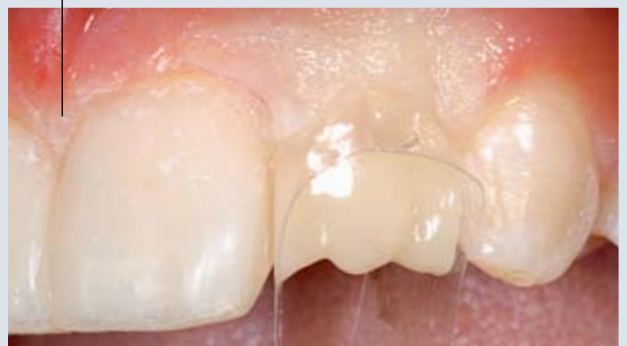7. Once the correct proportion and position were developed in the central incisors, the lateral incisors were treated.



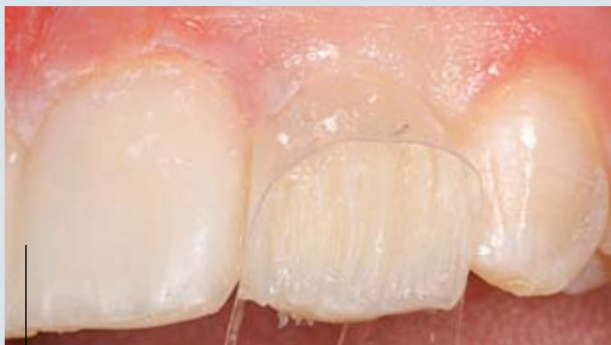8. Using a matrix placed subgingivally, uncured flowable resin was followed by dentin composite and cured.



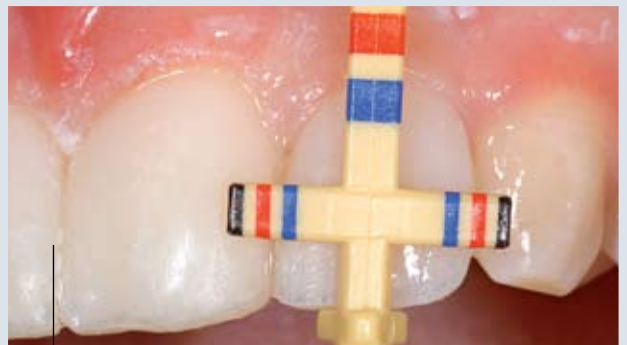9. Final dentin lobing was then completed for the lateral incisor.




10. An irregular layer of incisal composite was overlaid with an enamel layer.

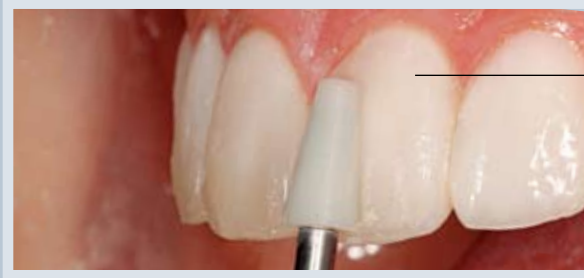

11. The aesthetic gauge showed the tooth was excessively wide, needing further modification.





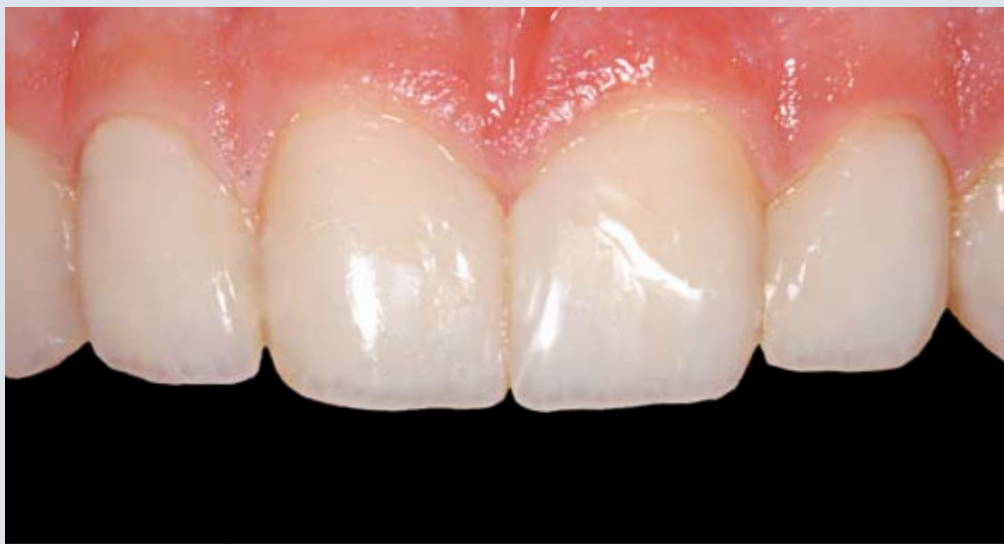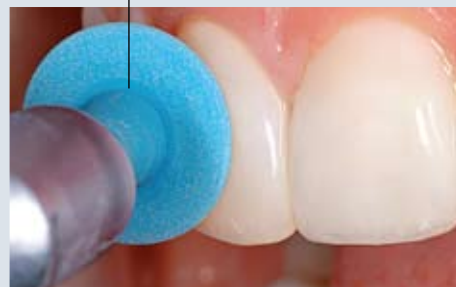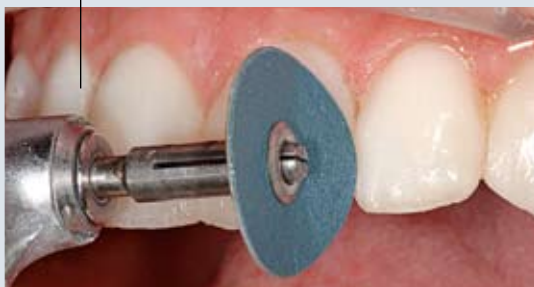12. A predictable armamentarium is necessary to ensure proper finishing and polishing of the anatomical restoration.



13. A Compo Roller (Kerr Corporation, Orange, CA) was used to contour the final layers of enamel composite in order to reduce shaping time.

14. Sof Lex Disks (3M ESPE, St. Paul, MN) were used to contour embrasures and refine the anatomy.

15. Final texture and polish were achieved with FlexiDisks (Cosmedent, Chicago, IL) for a premium shine.



16. Proper contours and proportions gave the patient's smile a more natural appearance with greater symmetry.