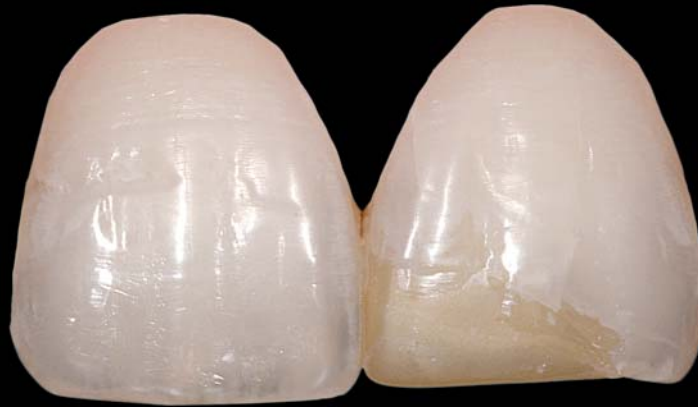

USE OF DIGITAL PHOTOGRAPHY TO IMPROVE COMPOSITE RESIN SELECTION AND MATERIAL PLACEMENT

Jack D. Griffin, Jr, DMD*



Digital photography has become essential in modern dentistry. In addition to providing enhanced communication between collaborating dentists, high-quality imagery can also be a valuable diagnostic tool in direct composite procedures. There are many composite systems currently available with various opacities, shades, tints, and physical properties, which can replicate almost any natural situation. As advances in material science have improved the performance of composite resins, it is the skill of the clinician that primarily influences the restorative outcome. The greatest obstacles lie in determining where to layer the various composites and envisioning the final result prior to placement. Digital photographs taken prior to and during treatment may assist the practitioner in shade selection and composite layering for natural-looking restorations.

Learning Objectives:

This article presents a case in which digital photographs assisted in the shade selection for a direct composite procedure. Upon completion of this article, the reader should:

- Recognize the benefits of capturing high-quality images prior to and during a procedure.
- Be aware of how digital photographs can assist in composite shade and layering technique selection.

Key Words: : direct composite resin, digital photography, shade selection, aesthetics

*Private practice, Eureka, Missouri.

Jack D Griffin, Jr, DMD, Eureka Smile Center, 18 Hilltop Village Center Drive, Eureka, MO 63025

Tel: 636-938-4141 • E-mail: Esmlcenter@aol.com

Contemporary composite resins, available in natural tooth shades and with favorable optical characteristics and clinical performance, provide practitioners with restorative materials that are increasingly predictable for use in operative dental procedures. Whereas material properties were once the challenging aspect of direct resin restorations, the diagnostic ability and clinical experience of the operator are now the primary determinants of restorative success.¹ Photographic evaluation of the patient's dentition, prior to and during direct composite placement, can aid the clinician in identifying and replicating the anatomy of the natural tooth or teeth—thereby improving the precision of the restorations.

When selecting a composite system (eg, Filtek Supreme, 3M ESPE, St. Paul, MN; Four Seasons, Ivoclar Vivadent, Amherst, NY; EsthetX, Dentsply Caulk, Milford, DE), it is important to consider those with multiple opacities and various shades, and the practitioner must have a plan as to where and in what quantities each material must be placed.² The currently available materials offer a variety of composite particle filler sizes and shapes that affect restoration strength and polishability and, when their indications are respected, can replicate almost any natural situation.^{3,6} A single, monochromatic composite may provide the patient with a serviceable restoration; tooth color nuances, patient preference, or clinician conviction, however, may warrant a more detailed and precise restoration.^{7,8}

Polychromatic layering of composite resin enables the clinician to effectively recreate the innate properties of the tooth structures, provided the material characteristics and proper layering techniques are understood.⁹ By coupling common photographic techniques with an understanding of these varying opacities and tints, composite restorations with natural detail may be created.⁹ The greatest obstacles lie in determining where to place the various composites and envisioning the final result prior to placement. In a Class IV case, there are often variances in tooth colors, opacities, and texture that make material choice and placement a challenge for the practitioner.¹⁰ Digital photographs represent an efficient method for the clinician to plan, deliver, and enhance such restorations.¹¹ As highlighted in the following technique, consultation using preoperative photographic images can provide the clinician with the vision needed to complete these restorations.

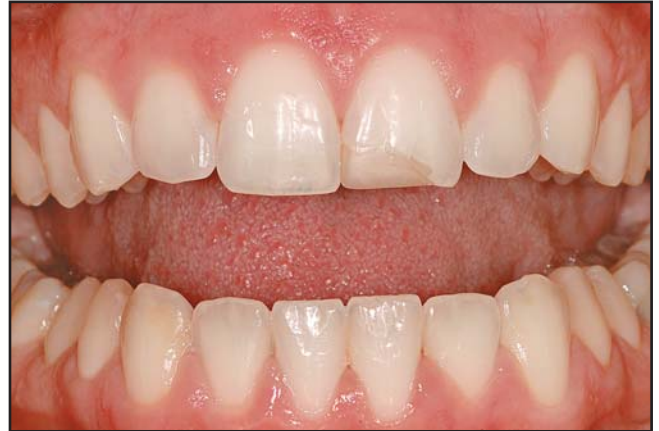

Figure 1. Preoperative view of a patient with a 14-year-old composite restoration that no longer satisfied her aesthetic demands.

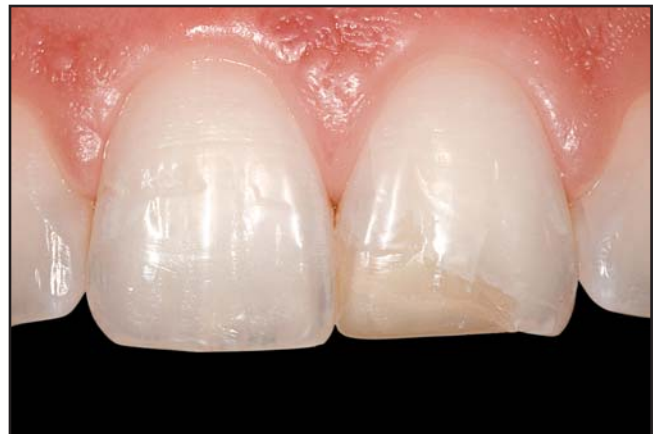

Figure 2. A high-resolution, magnified image can yield a greater sense of tooth character when examined away from operatory distractions.

With only a few images, and with less time than is normally required for the assistant to explain the procedure to the patient, digital images can be referenced and a restoration prescription quickly established. Following placement, similar images can be taken, non-distracted evaluation can be accomplished on a monitor, and a systematic outline for restoration enhancement can then be created. In the author's experience, these photographic steps enhance the restoration, precision, and speed.

Preoperative Blueprint Photography

In order to determine the true color and character of a tooth, distractions that can confuse the eye must be eradicated. These distractions may be extraoral (eg, operatory lighting, patient position, office commotion) or

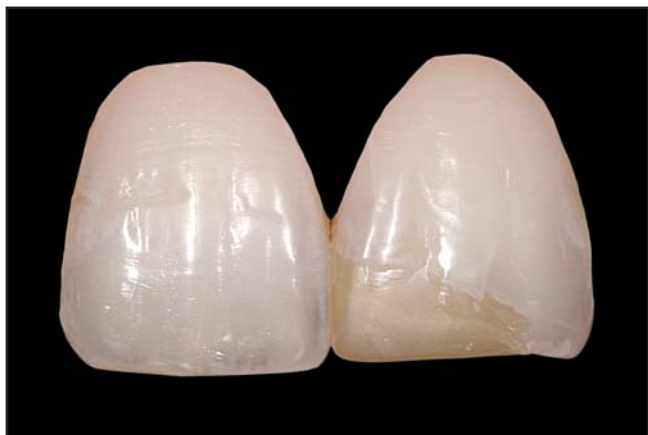

Figure 3. Removing soft-tissues from the image with photographic editing software may further enhance observation.

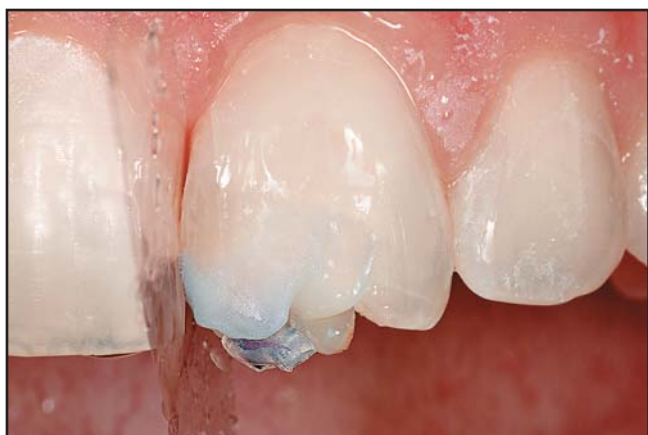

Figure 4. Various composites were tested to determine which material would deliver the desired opacity

intraoral (eg, soft tissue color, shadows, unnatural tooth lighting). Lighting, fatigue, influence of other tissues, and bias towards certain shades are all factors that must be overcome when focusing on the patient's needs. Well-composed images that may be reviewed on a large monitor away from treatment room distractions can ensure that an accurate plan is formulated.

For single-tooth shade matching, light control and tooth proximity are critical elements to be considered. The most important factor in a quality image worthy of color and incisal character evaluation is one in which light control is excellent. An overexposed image is essentially useless for tooth color and character evaluation.

Images in the following case were captured with an SLR digital camera in aperture priority "A" mode.

The f/stop adjustment dictates the amount of light entering the camera during the flash and provides an accurate control of the light reflected back from the tooth. Generally, this camera setting, along with proper flash and lens usage, can provide a detailed view of tooth character.

Multiple digital photographs may be captured, loaded on a computer, and analyzed effectively and efficiently. A consulting room, where the lights can be dimmed and a large monitor can be viewed, may be the ideal place to analyze treatment images. If this is not available, any large monitor where the clinician can evaluate the images without distraction may be beneficial in analyzing the case. It is the author's assertion that these few minutes may increase the accuracy of composite selection and reduce the trial and error involved with material placement.

Case Presentation

A 45-year-old female patient presented with a fractured central incisor and a composite restoration that had been placed by the author—with the intent of providing more definitive treatment at a later date—14 years previously. The restoration was a single-shaded hybrid composite that had served all functional purposes, but was unacceptable by today's aesthetic standards regarding staining, wear, and unnatural character (Figure 1).¹²

Extraoral and intraoral images were captured with a 6.1 megapixel digital SLR camera, a 105-mm macro lens, and a macro speedlight (ie, Nikon D70, Nikkor 105mm macrolens, SB-29s, Nikon, Rutherford, NJ). Extraoral and wide intraoral images were taken to document the preoperative condition of the patient, but not necessarily to aid in composite placement. Despite the diligent effort by the staff to select shades, it was difficult to precisely match colors and tints directly on the patient due to distractions that complicated proper evaluation.

Maximum close-up images were thus captured for thorough evaluation of tooth color, opacity, and incisal character. Gingival retractors were placed to prevent shadows during the exposure, and a contrastor (ie, PhotoMed, Van Nuys, CA) was held behind the teeth to decrease the unnatural lighting of the teeth from behind during the flash. The digital photographs were loaded into a computer and viewed on a large monitor, where

in tooth color, tints, and variations in opacity were noted. The maximum zoom, combined with proper lighting control, provided an excellent means of determining material placement (Figure 2).

To further ensure an accurate restorative prescription, nontooth tissues that may distract the clinician's eye were removed using a digital imaging software (ie, PhotoShop, Adobe, San Jose, CA) (Figure 3). The adjusted image was displayed in the treatment room according to a written color prescription similar to those provided to a dental laboratory for the fabrication of an indirect restoration. This evaluation occurred while the assistant mocked up composites of varying shades and opacities to confirm the restoration prescription.

Composite Layering With Digital Images

The existing composite was removed with a course diamond, and an irregular 3-mm to 4-mm bevel was placed to create a finish line that would conceal the fracture line following direct resin buildup. A composite system with three different opacities (ie, dentin, enamel, and incisal) and customization tints (ie, Renamel, Cosmedent, Chicago, IL) was selected, and confirmation of composite shades and opacities were performed. To accomplish this, the clinician placed the resin material on a non-bonded tooth and cured it (Figure 4). The trial materials were then removed, the tooth was etched with a 37% phosphoric acid, and a light-cured bonding agent was applied and air thinned (Figure 5).

Using a more opaque composite, the first dentin layer was placed in an irregular form with lobes, using the digital photography as a guide. This layer would provide the majority of the restoration's strength, impart basic internal color, form the internal tooth lobes, and conceal most of the restoration/tooth junction (Figure 6). The microhybrid resin was used in order to improve the restoration's ability to withstand intraoral forces; this layer would subsequently be covered with a microfill resin to instill a natural finish for the restoration.^{13,14} The dentin layer was undercontoured on the facial aspect to ensure that it remained 0.5 mm to 1 mm undercontoured after final shaping.

A low-opacity incisal layer, with 1 mm to 2 mm of overextension, was placed to restore the incisal edge (Figure 7). In order to build the innate characterizations of the tooth, the material was placed in an irregular manner,

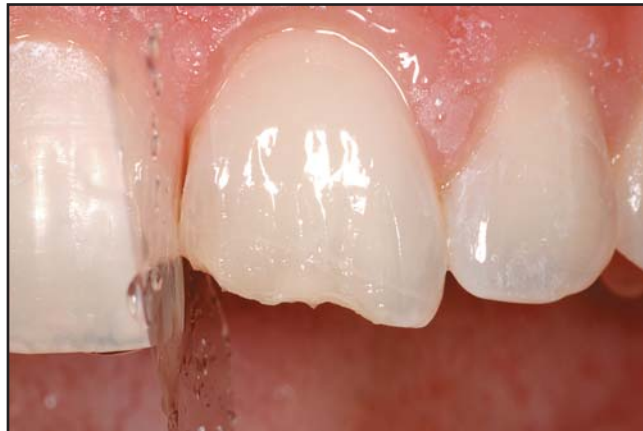

Figure 5. Following removal of the trial materials, an irregular, long bevel was used to facilitate acid etching and placement of a bonding agent.

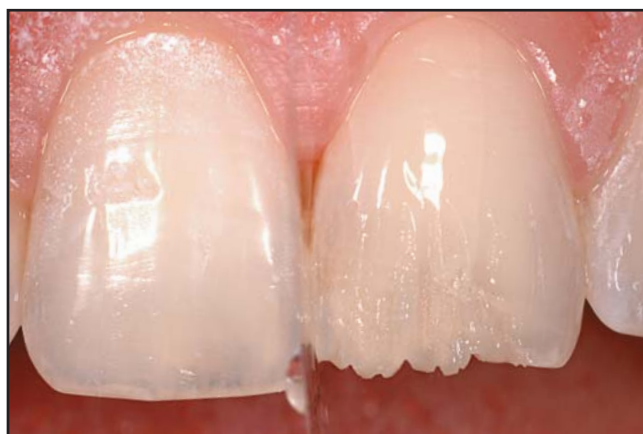

Figure 6. A composite with dentin opacity was used to form the majority of the lingual aspect and was intentionally left undercontoured prior to polymerization.

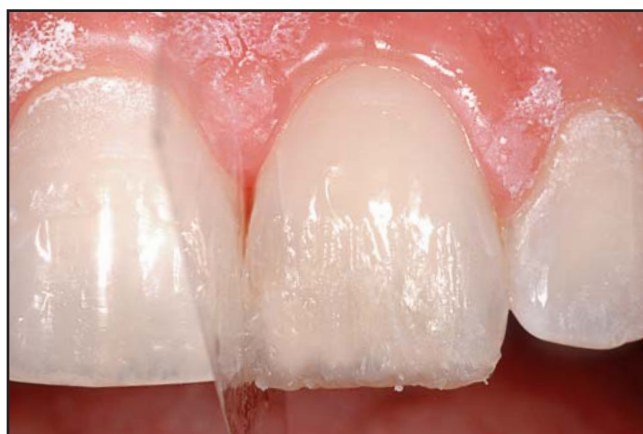

Figure 7. A low-opacity incisal composite was placed with a slight overextension to complete the length of the restoration and restore the incisal edge.

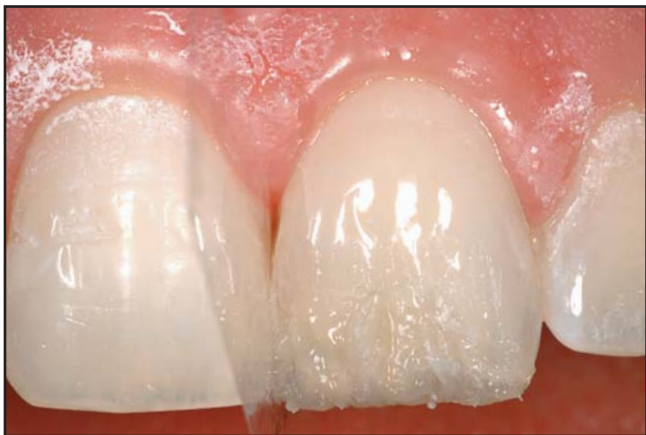

Figure 8. Various, custom, white opaque and honey-yellow tints were irregularly placed on the dentinoincisal composite framework.

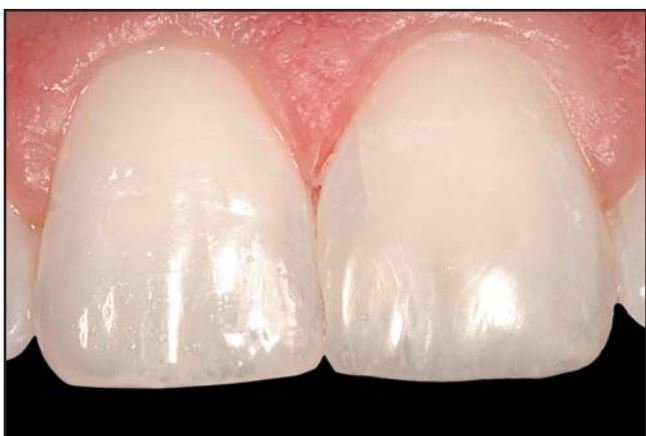

Figure 9. Because the restoration was still slightly undercontoured, sufficient space remained for the final enamel layer, which concealed ~~applied to conceal~~ the substructures and was overcontoured for finishing.

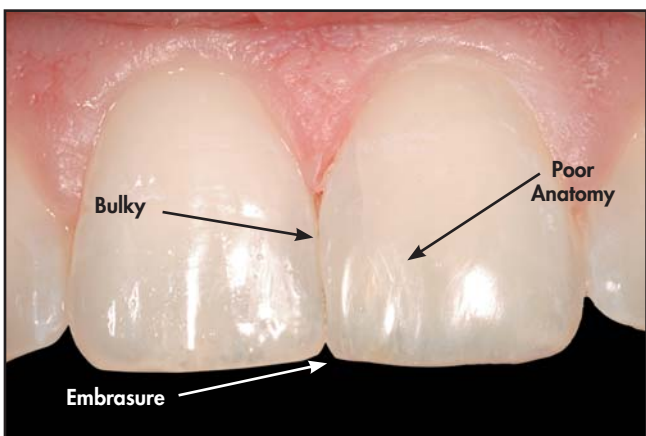


Figure 10. Following immediate shaping, a postoperative image was captured and analyzed. Final adjustments were determined away from operatory distractions.

with basic shaping from a composite instrument. Irregular grooves were also placed on the facial prior to curing. Very little of the material covered the facial aspect of the dentin shade, which allowed room for the final increments of composite resin. The junction of the dentin and incisal shades was confined within the desired finished contour to ensure that the transition could be concealed by the definitive resin buildup. A thin layer of custom-stain white opaque and honey-yellow (ie, Creative Color, Cosmedent, Chicago, IL) was then mixed and applied asymmetrically with a small brush (Figures 8 and 9). The goal of this material was to provide the internal colors seen on the adjacent teeth and to help conceal transition areas between incisal and dentin composite.

A final layer of enamel B1 microfill composite (ie, Renamel Microfill, Cosmedent, Chicago, IL) was placed, covering the entire restoration; this layer was slightly overcontoured to allow sufficient space for shaping and polishing. The restoration was light cured for 45 seconds from both the lingual and facial aspects.

Composite Finishing, Digital Critique, and Restoration Enhancements

Contouring was performed with a fine finish diamond bur and shaping disks. Embrasures were shaped and refined with three levels of finishing discs (ie, Soflex, 3M ESPE, St. Paul, MN), and interproximal areas were finished with a composite knife and abrasive strips. Care was taken to enhance the facial anatomy by developing subtle developmental indentations with rubber polishing cups, discs, and polishing paste to provide a natural surface.¹⁵ Several digital photographs were then taken using the black contrastor, retractors, and maximum close-up as previously described (Figure 10).

The results were briefly evaluated away from the distractions (eg, office commotion, lighting, patient positioning) of the operatory that could have been an obstacle to an accurate review of the procedure. The image was analyzed on a consultation-room computer monitor and obvious restoration deficiencies were marked (Figure 11). By referring to the analyzed images, the clinician was able to perform corrections in color, contour, and finish in a methodical and organized fashion to ensure that needed corrections were not missed (Figure 12). Photographic images formed the framework for these adjustments and made the difference between an acceptable restoration

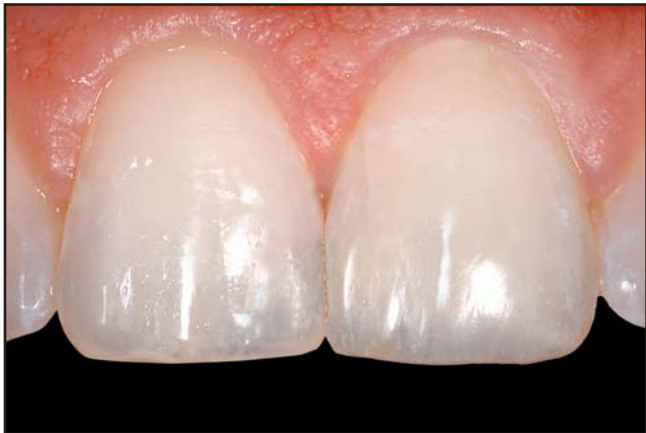

Figure 11. The restoration was then enhanced by adding composite, contouring, and finishing.

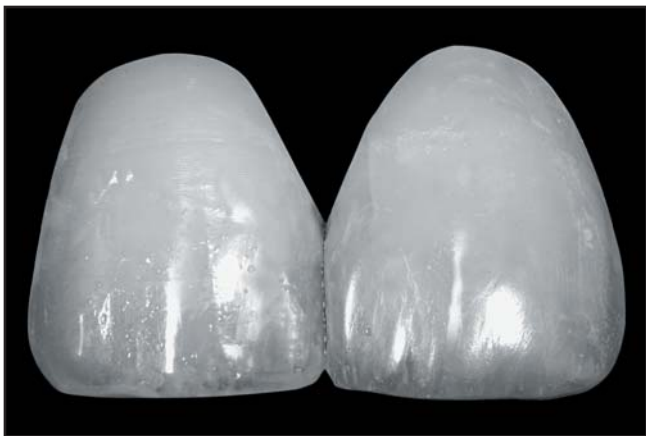

Figure 12. Grayscale imaging can be used to evaluate the restoration's value.

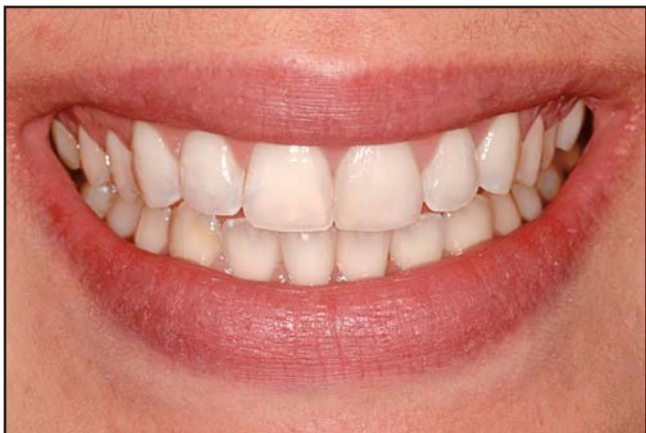

Figure 13. Postoperative smile appearance demonstrates harmonious integration and pleasing aesthetics.

and one that was excellent. (Figure 13). Tissue and color may also be removed from a postoperative image for a more thorough analysis.

Conclusion

By using quality digital images as a blueprint for material selection, a guide for composite layering, and a tool for self-critique and restoration enhancement, excellent composites can become much more attainable for many practitioners. The precision and quality of the restoration are worth the few additional minutes taken to capture quality images for planning and executing direct composite procedures.

Acknowledgment

The author declares no financial interest in any of the products cited herein.

References

1. Koczarski MJ, Corredor AC. Direct Posterior Composite Restorations: Simplified Success Through A Systematic Approach. *Pract Proced Aesthet Dent* 2002;14:1:87-94.
2. Dietschi D. Layering concepts in anterior composite restorations. *J Adhes Dent* 2001;3(1):71-80.
3. Jackson RD. Understanding the characteristics of naturally shaded composite resins. *Pract Proced Aesthet Dent* 2003;15(8):577-585.
4. Christensen GJ. Bonding to dentin and enamel where does it stand in 2005? *J Am Dent Assoc* 2005;136(9):1299-1302.
5. Terry DA. Direct composite resin restoration of adolescent class IV tooth fracture: A case report. *Prac Periodont Aesthet Dent* 2000;12(1):23-29.
6. Terry DA. Utilization of a small-particle composite resin for anterior and posterior restorations. *Pract Periodont Aesthet Dent* 2000;12(4):371-378.
7. Dietschi D. Free-hand composite resin restorations: A key to anterior aesthetics. *Pract Periodont Aesthet Dent* 1995;7(7):15-25.
8. Fahl N Jr. A polychromatic composite layering approach for solving a complex Class IV/direct veneer/diastema combination: Part II. *Pract Proced Aesthet Dent* 2007;19(1):17-22.
9. Fahl N Jr. A polychromatic composite layering approach for solving a complex Class IV/direct veneer/diastema combination: Part I. *Pract Proced Aesthet Dent* 2006;18(10):641-645.
10. Milnar F. A minimal intervention approach to the treatment of a class IV fracture. *J Cosmet Dent* 2006;21(4):106-112.
11. Griffin JD Jr. Assessing aesthetic composite veneer placement via digital photography. *Pract Proced Aesthet Dent* 2007;19(5):289-294.
12. Terry DA, Leinfelder KF. An integration of composite resin with natural tooth structure: The Class IV restoration. *Pract Proced Aesthet Dent* 2004;16(3):235-242.
13. Chyz G. Postorthodontic restoration of worn incisal edges. *Contemp Esthet* 2006;10(4):36-39.
14. Fahl N Jr. Achieving ultimate anterior esthetics with a new microhybrid composite. *Compend Contin Educ Dent* 2000;26(Suppl):4-13.
15. Da Costa J, Ferracane J, Paravina RD, et al. The effect of different polishing systems on surface roughness and gloss of various resin composites. *J Esthet Restor Dent* 2007;19(4):214-224.

CONTINUING EDUCATION (CE) EXERCISE No. 11

To submit your CE Exercise answers, please use the answer sheet found within the CE Editorial Section of this issue and complete as follows: 1) Identify the article; 2) Place an X in the appropriate box for each question of each exercise; 3) Clip answer sheet from the page and mail it to the CE Department at Montage Media Corporation. For further instructions, please refer to the CE Editorial Section.

The 10 multiple choice questions for this Continuing Education (CE) exercise are based on the article "Use of digital photography to improve composite resin selection and material placement" by Jack D. Griffin, Jr, DMD. This article is on Pages 359-364.

- 1. Which of the following is NOT a reason to perform polychromatic restorations instead of monochromatic ones?**
 - a. High patient expectations.
 - b. Variances in tooth character.
 - c. Clinician conviction about restoration detail.
 - d. Ability to charge premium fees.
- 2. Which of the following difficulties is eased by the use of well-composed digital images?**
 - a. Extraoral distractions such as operatory lighting and office commotion.
 - b. Intraoral distractions (eg, shadows, unnatural lighting).
 - c. Time of trial and error in restoration placement.
 - d. All of the above.
- 3. What is the term for the single camera setting that is used to control light entering the camera in "A" mode while acquiring an image?**
 - a. f/stop.
 - b. Shutter speed.
 - c. Exposure compensation.
 - d. ISO setting.
- 4. Which of the following factors does NOT need to be overcome when choosing accurate tooth shades and character?**
 - a. Unnatural lighting.
 - b. Material handling.
 - c. Practitioner fatigue.
 - d. Staff bias towards certain shades.
- 5. Which of the following best describes the use of digital photography in planning and forming a placement blue print?**
 - a. Digital photography takes excessive time and decreases practice efficiency.
 - b. Digital photography requires a separate photography appointment to capture images and plan for the case.
 - c. Digital photography is best done with a muslin background, reflectors, and soft box lighting.
 - d. Digital photography takes about the same amount of time as the assistant takes to try shades on the tooth.
- 6. What is the most common limiting factor in creating highly aesthetic direct resins with respect to today's materials?**
 - a. Inability to form a dependable bond of composite to enamel.
 - b. Unrealistic polishability of modern composite systems.
 - c. Clinician inexperience or incomplete interpretation of needed opacities and shades.
 - d. Biologic width violation.
- 7. Which of the following statements regarding the dentin layer of composite is true?**
 - a. It is relatively clear and meant to provide depth of color.
 - b. It is high in opacity and used to block light transmission while forming lobes within the restoration.
 - c. It is usually the final layer placed, to provide increased restoration.
 - d. It is mixed with stain to form restoration texture and blending.
- 8. What is the best way to apply character stain?**
 - a. With a plastic instrument.
 - b. In very straight, regular patterns.
 - c. On the restoration surface to provide surface character.
 - d. Underneath the final composite layer to provide internal character.
- 9. Which of the following is a key use of photography during restoration placement?**
 - a. To honestly evaluate restoration appearance.
 - b. To form an outline of needed restoration enhancements.
 - c. To give the practitioner a chance to scrutinize the composite away from operatory distractions with an enlarged image on a large monitor.
 - d. All of the above.
- 10. What is the main goal of incorporating routine photography in direct composite placement?**
 - a. Increase precision and quality of direct restorations.
 - b. Make composites more financially rewarding.
 - c. Substantially increase the number of patients who ask for aesthetic restorations.
 - d. Use underused photography equipment.