

Efficient, Conservative Treatment of Symptomatic Cracked Teeth

CE 2

Abstract: *Every practice has patients who complain of cold sensitivity and pain on biting while showing no obvious signs of irreversible pulpitis. After loading each cusp and fossa in a symptomatic quadrant and ruling out pulp and periodontal pathology, definitive treatment can be performed to alleviate the patient's symptoms in a consistent, conservative manner using esthetic computer-aided design/computer-aided manufacturing porcelain restorations. Single-appointment definitive restorations can be advantageous for the patient because of the elimination of many steps involved in laboratory fabrication of porcelain or metal restorations.*

Jack D Griffin, Jr, DMD, FAGD
Private Practice
Eureka, Missouri

Patients regularly complain of painful teeth, and it is prudent to determine the cause and to provide correct treatment. Cracked tooth syndrome (CTS) refers to an incomplete fracture of a vital posterior tooth that involves the dentin and may extend to the pulp.¹ Patients often report a history of teeth that occasionally give a sharp pain when biting certain foods. Sometimes they can specifically identify the offensive tooth, but often they cannot tell where the pain is coming from.

Often location and the extent of the fractures are difficult to evaluate, and various diagnostic methods must be used.² Great restorative treatment cannot overcome a faulty diagnosis, and no treatment can succeed if the diagnosis is incorrect.³ Patient history, a thorough clinical exam, pulpal testing, and radiographs all combine with training and experience to create an effective treatment plan. Recommended treatment for cracked teeth has ranged from simple occlusal adjustments to varied restorative and endodontic therapies.⁴

Diagnosis

A thorough history from the patient perspective is critical. How long has there been pain? Is it worse when lying down? Is it throbbing or spontaneous? Does it hurt only when eating or grinding? Has the patient had pain in this area in the past? Is the sensation occasional or constant? Does the pain come from a specific area, or is it hard to locate? Data from patient history is assimilated and recorded to aid in a methodical diagnosis.

Diagnosis of CTS should be gathered from multiple clinical tests. Conservative treatment of cracked teeth can only be attempted after ruling out pulpal or periodontal pathology. If radiographic examination indicates a periapical lesion or if the patient gives a history of lingering cold sensitivity, heat-induced pain, throbbing, or spontaneous pain, irreversible pulpitis is indicated and endodontic treatment should be considered.⁵

Only when prudent clinical testing rules out irreversible pulpitis or periodontal pathology can conservative restorative options be considered. Clinical tests of the symptomatic quadrant could include loading each cusp with a cotton roll or bite stick, inspection with magnification, transillumination, intraoral cameras, selective tooth banding, or staining.⁵ The critical diagnostic factor is to locate the specific cusp or cusps that are causing the pain.

Learning Objectives:

After reading this article, the reader should be able to:

- describe clinical characteristics of cracked teeth.
- clinically distinguish teeth with symptomatic fractures with irreversible pulpitis from those without irreversible pulpitis.
- discuss a diagnostic protocol to specify fractured cusps needing treatment.
- explain why single visit porcelain restorations may be beneficial over traditional full coverage crowns for treatment of cracked teeth.

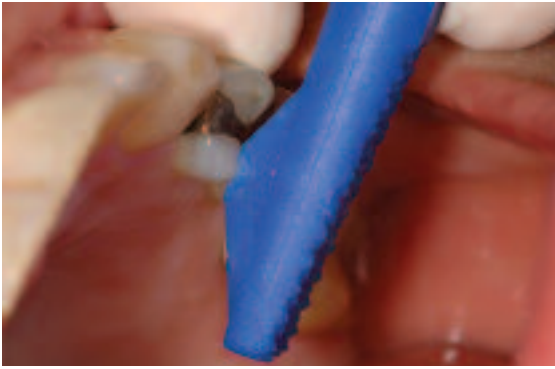


Figure 1—All teeth in a symptomatic quadrant are checked with the Tooth Slooth IIa after ruling out pulpal or periodontal pathology. The dimpled end is placed on every cusp tip and held there as the patient closes.

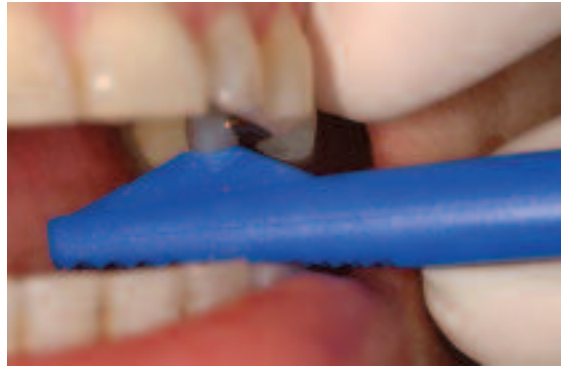

Figure 2—The patient is asked to bite straight down with firm pressure. Each cusp is checked and re-checked in a suspect quadrant until the symptoms the patient complained of are reproduced.

Characteristics of Cracked Tooth Syndrome

- History of sharp pain when eating or biting
- Sporadic pain
- Mild or intense nonlingering sensitivity to cold
- Absence of heat-induced sensitivity
- Absence of radiating, throbbing, or lingering pain
- Occasional pain when grinding teeth or excursive movements
- Pain repeated with bite stick, cotton roll, or other clinical loading
- Tooth segments do not physically separate during clinical loading
- No periapical pathology on radiograph
- No periodontal pathology with probing, and no soft-tissue swelling

Lingering, throbbing, or spontaneous, or radiographic pathology coupled with 1 or more of the other symptoms indicates the need for root canal therapy.⁷ If any of the symptoms listed in Table 1 are reported, endodontic therapy is indicated and recommended.⁸ Once the clear need for endodontic therapy is ruled out, the tooth or cusp causing biting pain should be located. Orangewood sticks, cotton rolls, burlew wheels, and many other tools have been used for years to simulate biting pain on a patient.¹

The goal of conservative treatment is to keep the cracked parts of the tooth from moving apart from each other and causing pain while preserving as much natural tooth as possible. Identifying a particular cusp or cusps allows the practitioner to treat the part of the tooth that is causing the pain without reducing the entire tooth.

The Tooth Slooth II^a and the Fracfinder^b are items used in dentistry to reproduce biting forces on teeth or individual cusp tips, and can be an important part of diagnosing and conservative treatment planning of symptomatic cracked teeth. They can be used in place of sticks, cotton rolls, or other tooth loading.⁹ It is a 2-ended instrument, with a dimpled concave end for placing directly on cusp tips and a pointed end that can put pressure in a specific area of a fossa.¹⁰ The instrument is adept at identifying not only which tooth is symptomatic, but more importantly, which part of a tooth is causing the pain. Even if transillumination, photography, or magnification reveals a tooth fracture, the clinician must still determine if it is that particular fracture, crack, or craze that causes the patient discomfort.

The concave end of the instrument is placed on each cusp in a suspect quadrant (Figure 1). The patient is then asked to close straight onto the stick and bite with firm pressure. Then the patient response is recorded (Figure 2). When loading the symptomatic cusp, the pain is readily noticeable by the patient as similar to that which is felt when the patient eats or bites. Every cusp must be loaded methodically so that an acute diagnosis can be made. Every cusp is checked at least twice to verify the sensations; the treatment plan should include at least that cusp in the final restoration.

The pointed end of the instrument is used to load each occlusal restoration and every central fossa to determine if the tooth has a mesial-distal fracture (Figure 3). In the same way, the patient closes with firm pressure, trying to repli-

^aProfessional Results, Inc, Laguna Niguel, CA 92677; (949) 249-3705

^bDenbur, Oak Brook, IL 60522; (800) 992-1399

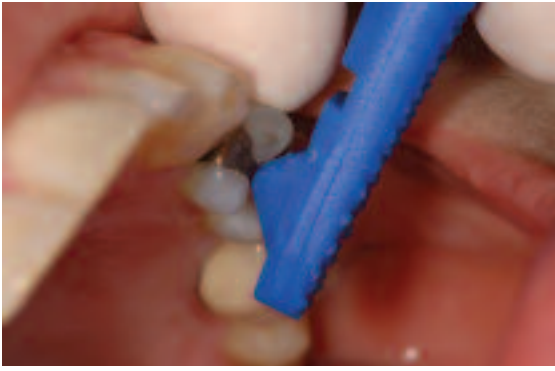

Figure 3—The pointed end is then used to load each central fossa and all occlusal fillings. The Tooth Slooth is held firmly on the fossa or filling while the patient closes.

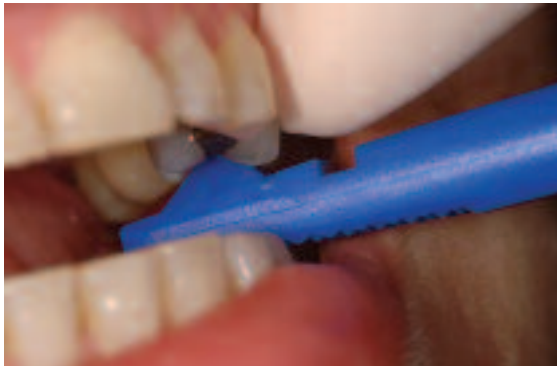

Figure 4—The patient bites down and results are recorded. Even though a positive test may have been given on a cusp tip, the fossa and fillings also must be checked to determine the extent of the restoration.

cate the symptom (Figure 4). Occasionally, newer posterior composites can cause CTS-type pain when loaded because of inadequate bonding of the restoration and consequential dentinal tubule fluid movement. This would indicate that the restoration should be replaced. Should the central fossa be symptomatic, a treatment plan must be made to at least replace the central fossa filling, and may include bonding or covering all cusps to prevent propagation of a mesial-distal fracture.

If symptoms have not been reproduced by the patient at this point, the pointed end of the instrument is placed on each fossa and the patient is asked to bite with firm pressure and grind the bite stick from side to side. This places a force perpendicular to the long axis of the tooth and can locate a painful fracture by loading the tooth obliquely. Should symptoms still not be reproducible, no other treatment is done at this time and a follow-up appointment should be made to repeat the examination.

Restorative Techniques

Once the symptomatic tooth or cusp is identified, there are multiple treatment options. The goal of treatment is to immobilize the segments of the tooth that move on loading, which can be done in a variety of restorative ways.¹ Occlusal adjustment, preparation of the tooth and temporary placement, orthodontic banding, bonded filling material, partial tooth coverage with porcelain or metal, or full tooth coverage with porcelain or metal have all been suggested for CTS treatment.¹¹

There are many esthetic reinforced porcelains that have proven quite successful, including IPS Empressc, Procerad, and Finessee. These restorative materials can be bonded onto a tooth and preparations can be designed that preserve healthy tooth structure. These materials involve tooth preparation, impressions, temporary fabrication, temporary maintenance, laboratory dependence, a second clinical appointment, temporary removal, porcelain try-in, tooth conditioning, cementation, adjustment, and polishing.

Because of the trend in dentistry to preserve tooth structure and the demand by the public for tooth-colored restorations, single-appointment porcelain fabrication and cementation can be a successful option for the treatment of these teeth. Cerec computer-aided design/computer-aided manufacturing (CAD/CAM) porcelain restorations have had over 20 years of scrutiny by the dental community and have proven to be reliable, cost effective, and very esthetic restorations.¹² Indirect CAD/CAM, single-visit restorations have proven to be very successful for many years.¹³

Because the Cerec system completes the restoration in 1 visit without fabrication and maintenance of less-than-ideal fitting temporaries, there is potential for less sensitivity than traditional crown-and-bridge procedures. This is particularly important in cases of suspected fracture-induced sensitivity where pulpal trauma seems to be cumulative and the reduction in tooth stresses is certainly prudent. Restoring with a definitive restoration in 1 appointment can lessen the chances of bacterial invasion from microleakage along the fracture, which may increase the chances of pulpal necrosis.¹⁴ There is also a reduction in tooth manipulation from a second appointment of anesthesia, temporary removal, tooth isolation, dentin exposure to saliva, drying, and restoration adjusting.

Potential Pulpal Advantages of 1 Visit

CAD/CAM Porcelain Restorations

- No irritation from traditional temporary fabrication and cementation.
- Less potential salivary and bacterial invasion from poor-fitting, broken, leaking, or displaced temporaries.
- No pulpal stress from second appointment cleaning, drying, bacterial exposure, or handpiece trauma.
- Esthetic, rigid, definitive restoration that reduces flexure of tooth.
- Materials are well-designed for conservative preparations that lessen iatrogenic pulpal stresses from more aggressive therapy.
- The restoration is bonded to tooth, which seals dentinal tubules and decreases chance of bacterial invasion.

Patient Preparation for Future Endodontic Treatment

Many patients with CTS symptoms have been treated with this same method by the author, resulting in pain-free teeth. Even so, despite methodical history and diagnosis, there have occasionally been attempts at conservative treatment, only to require endodontic treatment weeks, months, or years later. Patients must be warned at treatment planning that there is always the chance of pulpal damage to the tooth that has not yet progressed to the point of needing endodontic therapy diagnostically, but that it may be necessary in the future.

Should a porcelain restoration be placed and endodontic therapy be needed in the future, the clinician must determine if the access hole can be restored by bonding composite to the porcelain, or if a new restoration is needed for strength. If a new restoration is needed, the lab fee would be the only charge to the patient after the fees for endodontic therapy and post/build-up. If Cerec is used as in these cases, the material fee for the new milling is only \$25 to \$35. These fees are at the discretion of the practitioner as long as the patient is aware of the cost before treatment begins.

The following cases demonstrate the treatment of teeth demonstrating CTS symptoms without signs of irreversible pulpitis using bonded CAD/CAM partial coverage porcelain restorations. These cases are seen routinely in many practices. In each case, patient symptoms were alleviated without the need for endodon-

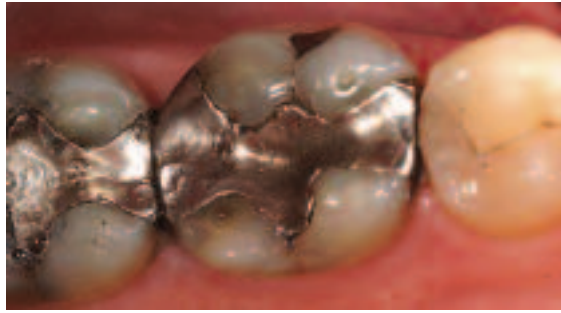


Figure 5—Examination revealed sharp pain reproduced when loading both buccal cusps of tooth No. 19. All other cusp tips or fossa were checked in this quadrant and found to be asymptomatic.

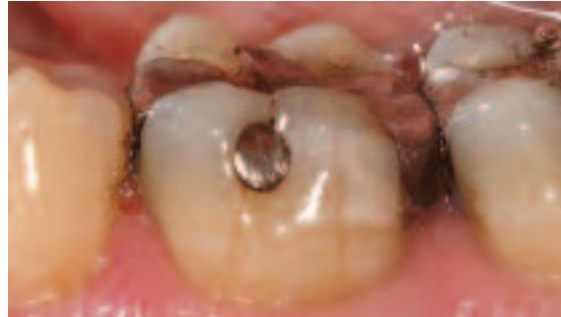

Figure 6—The buccal view shows craze lines running vertically down each cusp.

tic therapy, surgery, or extraction. The following cases were treated using the same method within a few weeks of each other. Most importantly, they all had no sensitivity to eating or cold for at least 2 years after treatment. The success of these restorations was the result of thorough and accurate diagnosis and conservative restorative treatment.

Case 1

A patient had complained of occasional pain on biting and cold sensitivity for many months, and had reached the point of never chewing on the left side of his mouth. There was no report of spontaneous or radiating pain, lingering thermal pain, swelling, or other pain. Radiographs revealed no obvious bone destruction under the roots, and there were no signs of periodontal pathology with inspection and probing. It was easy for the patient to identify tooth No. 19 as the source of the pain by pushing on it with a finger. A clinical exam revealed large mesio-occlusal distal-buccal amalgam restorations on teeth Nos. 18 and 19 (Figure 5). From a buccal view there were visible craze lines running vertically under both facial cusps of the first molar (Figure 6). There were no signs of periodontal or periapical pathology

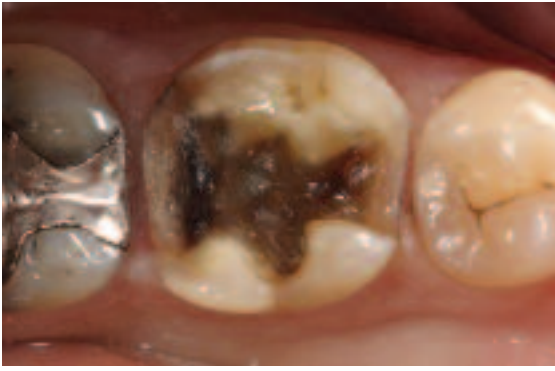

Figure 7—Initial preparation included removing the amalgam and reducing only the symptomatic cusps. Caries indicator was then used and the tooth was inspected for large cracks and decay.

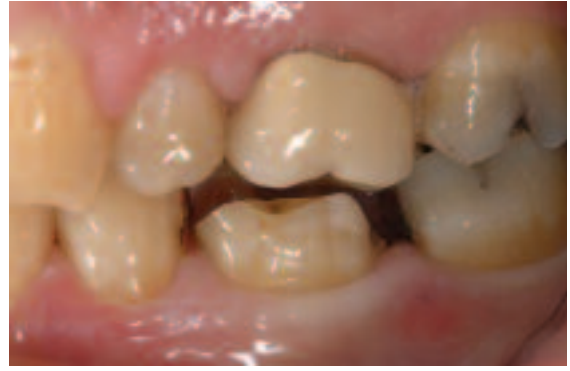

Figure 8—After completion of the restoration there was a minimum of 2 mm clearance in all excursive movements, and all margins were rounded shoulders with no internal sharp line angles.

from radiographic and clinical examination.

Diagnosis

Although the patient was sure which tooth was causing the pain, time was taken to load every cusp and fossa in the quadrant with the dimpled end of the Tooth Slooth II. The “sharp, stabbing” pain the patient experienced during eating was reproduced when both buccal cusps of tooth No. 19 were loaded. Neither of the lingual cusps reproduced the same pain, although the pointed end of the Tooth Slooth in the central fossa of the restoration produced a similar pain. These cusps were checked again, with positive results. No other teeth were sensitive to this testing.

Preparation

The lingual cusps were left in place because they were asymptomatic and there was at least 1 mm to 2 mm of healthy dentin supporting the enamel. Preparation did not include removing healthy tooth structure to obliterate the craze lines on the facial, but to remove any diseased tooth and to cover the symptomatic cusps. Drilling away all potential craze lines or cracks is unnecessary and may induce iatrogenic pulp trauma. The cracks were removed until a sharp explorer could not detect the separation of tooth. This indicated that tooth structure on both sides of the fracture was well-approximated. Care was taken to remove all decay and old restorative material within the tooth for proper

bonding, but the craze lines on the mesial and distal boxes were left intact because they were free of caries and well-approximated (Figure 7). All amalgam, base material, and decay were removed and the symptomatic cusps were reduced at least 2 mm occlusally to provide ample clearance for porcelain thickness during excursive movements (Figure 8). The buccal and interproximal margins were rounded shoulders of about 2 mm to give ample porcelain thickness for resistance to breakage. All internal points and angles were rounded to decrease stress accumulation within the porcelain.

Treatment

There are 3 main choices for Cerec restorative materials: Vita Mark II^g, ProCAD^c, and Paradigm MZ100^h. Vita and ProCAD are porcelains with similar handling, bonding, and milling characteristics. ProCAD is very similar in characteristics to IPS Empress^c with similar wear to enamel.¹⁴ Vita and ProCAD porcelains can be polished to a high luster using various rubber polishing points and brushes. Paradigm is MZ100 composite, which has excellent wear and esthetics but may not have the polish durability or wear resistance that porcelain has when occluding with a porcelain-fused-to-metal crown.¹⁵

The prepared tooth was powdered with titanium dioxide reflecting powder and scanned into the Cerec computer by the acquisition unit. In about 5 minutes the restoration design was completed in the Dental Database mode. This design mode uses anatomy of adjacent teeth and a computer stored library of data to propose a restoration (Figure 9). The anatomy, marginal ridge heights, and contacts were

^gIvoclarVivadent, Amherst, NY 14228; (800) 533-6825

^cNobel Biocare, Yorba Linda, CA 92887; (800) 993-8100

^eDentsply/Ceramco, Burlington, NJ 08016; (800)487-0100

^fSirona USA, Charlotte, NC 28273; (800) 659-5977

^gVita Zahnfabrik, Germany, distributed in US by Patterson, St Paul, MN 55120; (800) 325-3184

^h3M Espe, St Paul, MO 55144; (800) 634-2249

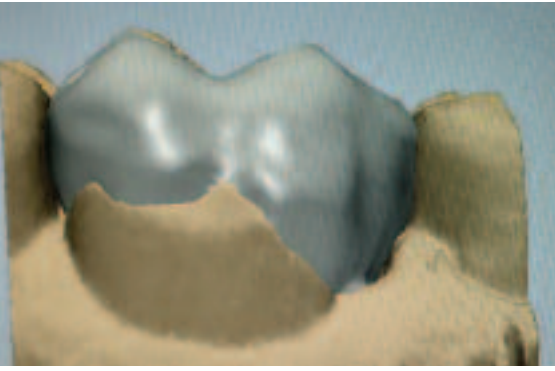


Figure 9—Cerec “Dental Database” design mode was used. The computer proposed this design according to a library of computer data and the anatomy of the adjacent teeth.

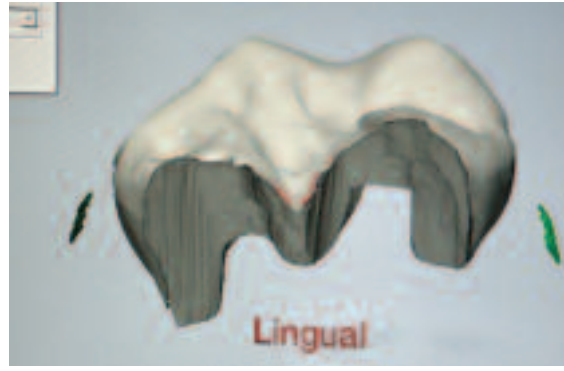


Figure 10—After operator editing, the restoration was finished and ready to be milled. A minimum of 1.5 mm to 2 mm of porcelain was incorporated into the design for ample porcelain strength.

checked and enhanced and the final restoration was inspected on the computer screen (Figure 10). Milling of Vita Mark II⁶ porcelain was completed in about 20 minutes. This Vita porcelain is reported to have excellent properties and great esthetics, and to wear opposing teeth comparably to enamel.¹⁵

The porcelain was tried in, contacts adjusted, and fit verified with very little adjustment. A metal Hawe Adapt SuperCap Matrixi was used to isolate the tooth and control the flow of the composite luting material to help ensure unhindered flossing. A Dry Tip^j was placed on the buccal to retract and control parotid moisture while a Denta Pop^k was inserted on the lingual of the tooth to allow the patient to relax the mandible, keep the patient’s mouth open, and to retract the tongue. FlexiWedges^l were used to secure the matrix and prevent crevicular leakage (Figure 11).

A nonetch dentin bonding system helps reduce some of the potential causes of postoperative bonding sensitivity. Some of the reasons why nonetch bonding systems may decrease iatrogenic sensitivity are:

- Dentinal smear layer left unviolated
- dentinal tubules are never “unsealed”
- less chance of gingival bleeding from caustic phosphoric acid so less chance of contaminated margin
- no chance of leaving phosphoric acid on tooth after incomplete rinsing
- decreased chance of desiccation when using a “moist dentin” bonding system

Simplicity^m, Clearfil SE bondⁿ, and Xeno III^o are self-etch dentin adhesives; a separate phosphoric acid etch step is not needed.¹⁶ In the author’s experience, Simplicity works well

for Cerec bonding and has caused virtually no tooth sensitivity in cases like this. Simplicity Part 1 primer was applied to damp dentin according to the manufacturer’s directions. Next, Part 2 bonding agent was applied, air thinned well, and cured for 20 seconds. Self-etch adhesive systems offer several advantages over traditional phosphoric acid etch systems. The smear layer is not removed, which may decrease the potential for dentinal tubules left open, subsequently causing sensitivity.¹⁷

The Vita porcelain was hydrofluoric acid-etched for 2 minutes, rinsed well, and thoroughly dried. Then a silane coupler was applied and dried after 10 seconds. Simplicity Part 2 resin was applied, air dried well, and light-cured for 20 seconds. According to the manufacturer, Build-It FR^p is a dual-cure, resin build-up material that has a film thickness of 30 μ m. Insure^q and Calibrao are dual-cure resin luting agents with low film thicknesses that work well for porcelain bonding. Unfortunately, they have to be hand-mixed and cannot be directly injected into the preparation.

Build-It FR was placed directly into the matrix from the automix gun (Figure 12). Before setting of the luting material, the restoration was vibrated into place with a Sonic Flex 2000^r hand-piece with a cementation tip for 5 seconds with firm pressure (Figure 13). This sonic vibration

ⁱKerr/Hawe, Orange, CA 92867; (714) 516-7400

^jMolnlycke Health Care, distributed in US by Microscopy, Kennesaw, GA 30144

^kPatterson Dental, St Paul, MN 55120; (800) 325-3184

^lCommon Sense, Nunica, MI 49448; (888) 853-5773

^mApex, Sandwich, IL 60548; (877) 273-9123

ⁿKuraray, New York, NY 10022; (800) 879-1676

^oDentsply/Caulk, Milford, DE 19963; (800) 532-2855

^pPentron, Wallingford, CT 06492-0724; (800) 551-0283

^qCosmedent, Chicago, IL 60611; (800) 621-6729

^rKaVo, Lake Zurich, IL 60047; (888) 528-6872

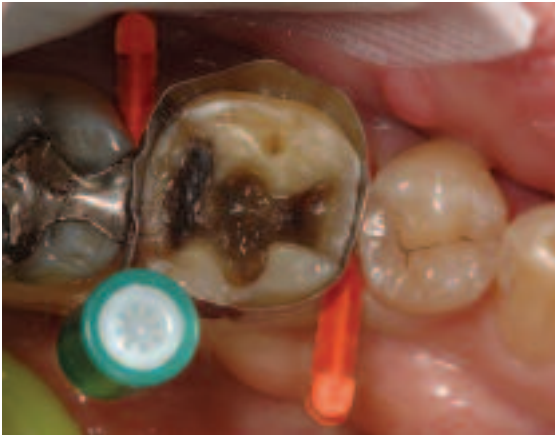

Figure 11—A matrix was placed on the tooth and secured with wedges. The matrix provides isolation for the tooth and helps ensure that the luting agent will not block embrasures and hinder flossing.

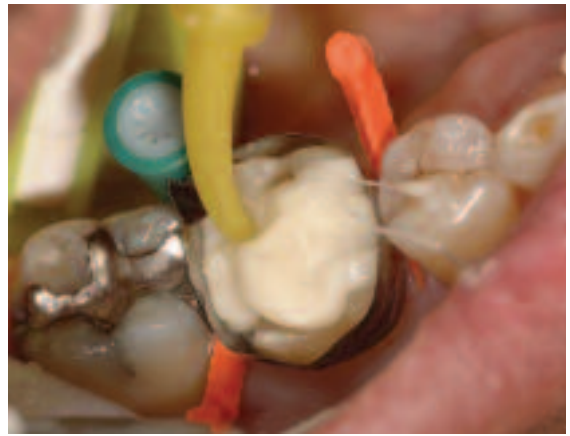

Figure 12—Build-It FR is injected directly into the matrix after the bonding agent is applied and cured.

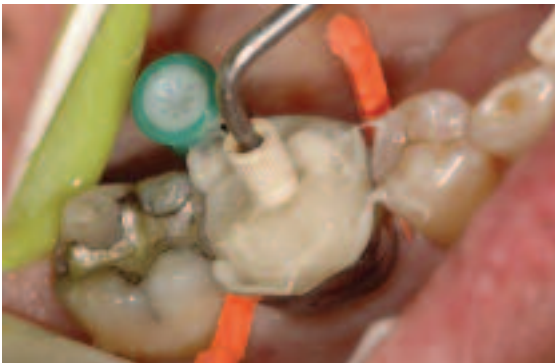

Figure 13—A cementation tip on an ultrasonic scaler is used to ensure complete seating of the restoration and to apply pressure to compensate for the thickness of the matrix band.

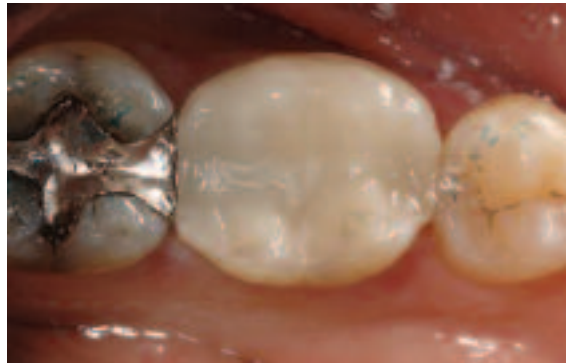

Figure 14—The restoration following clean up and bite adjustment. This is followed by anatomy fine tuning with a finishing diamond and then polished with rubber points.

helps to ensure complete seating of the restoration and may reduce the marginal cement line thickness and decrease the chance of voids under the restoration.

The curing light was turned on by the assistant and handed to the dentist. The tooth was then approached slowly to reduce negative polymerization forces and white lines near the margins.¹⁸ The first curing lasted 10 seconds from the occlusolingual with an Optilux 401ⁱ and a turbo tip. The band was then loosened but not removed; curing was done for 10 to 20 seconds from the facial and lingual.

Anatomy directly from the milling machine will need fine tuning once the occlusion is checked in all excursive movements (Figure 14). The occlusion was adjusted and contours were refined with a football diamond. The final anatomy was then placed with a finishing diamond, and porcelain polishing was initiated with a white stone^s, high-speed handpiece, and

copious water. The porcelain was then polished with wet Dialite^t cups and points. A final curing was done for 10 seconds each from the facial, lingual, and occlusal aspects to ensure complete setting of the bonding materials. From start to finish, the restoration took a total of 30 minutes of dentist time and 30 minutes of assistant and anesthesia time.

Follow-up

At the 2-year recall the patient remained symptom-free, and has had no further sensitivity to bite or temperature since the restoration was placed (Figure 15). After 2 years the margins remained stable, anatomy was very good, the color was acceptable, and the buccal craze lines had not increased in size (Figure 16).

Case 2

A patient presented with a “sharp, stabbing pain” when eating food on one side of the mouth, but was unsure from which tooth the pain was originating. An exam revealed large

ⁱShofu, San Marcos, CA 92069; (800) 827-4638

^sBrasseler USA, Savannah, GA 31419; (800) 841-4522

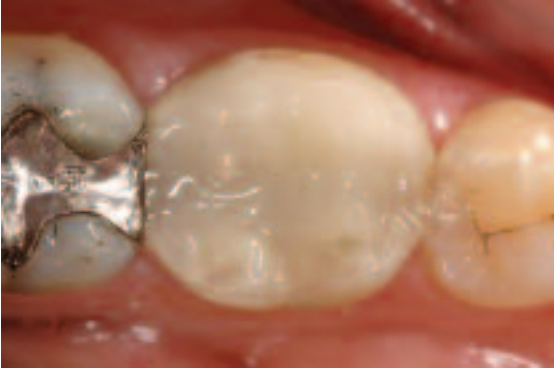

Figure 15—After 6-month recall appointment and follow-up for over 2 years, the tooth has remained symptom-free, with no eating or drinking limitations.

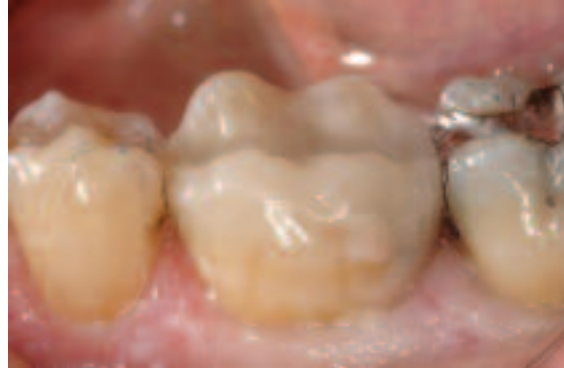

Figure 16—Buccal view more than 2 years after treatment shows excellent margins, reasonable wear, and no obvious growth of buccal craze lines.

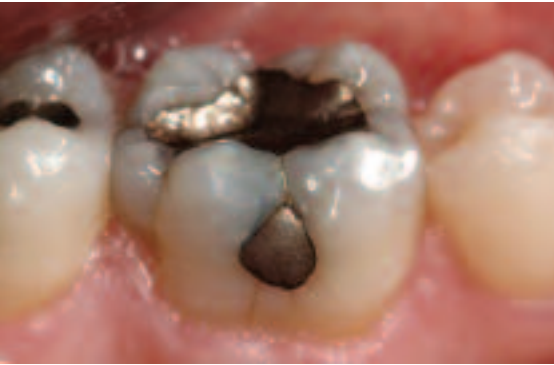

Figure 17—Symptomatic tooth with sharp pain when both lingual cusps were loaded and moderate pain when the restoration and central fossa areas were loaded. Some craze lines were found on the buccal from the pit amalgam toward the gingival.

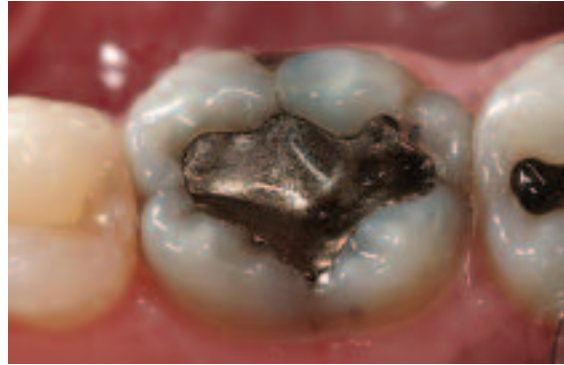


Figure 18—There are obvious cracks on both mesial and distal marginal ridges. The amalgam shows signs of leakage and has decay near its margins.

failing amalgam with leaking margins on tooth No. 19, and a smaller occlusal-buccal amalgam on tooth No. 18. Several craze lines were noticed on the facial and lingual, but all tooth segments seemed to be approximated well when the explorer passed over them (Figure 17). Larger cracks were seen on the mesial marginal ridge and the distal marginal ridge and running vertical down the lingual (Figure 18).

Diagnosis

Irreversible pulpitis was ruled out with history, clinical tests, and radiographs. Percussion with a mouth mirror produced slight sensitivity, and loading with a Tooth Slooth II reproduced the sharp pain on both lingual cusp tips of the first molar. The buccal cusps and central fossa of the amalgam gave slight loading pain. No other cusps in the quadrant gave a positive response. Because of the loading pain of all 4 cusps and the amalgam, they were all treatment planned for porcelain coverage.

Preparation

“Correlation” is another design mode in the Cerec system that allows the practitioner to copy the anatomical features of the preoperative condition of the tooth. Titanium dioxide powder is applied to the tooth while waiting for profound anesthesia. The non-prepped, pre-treatment morphology of the tooth is acquired with the Cerec acquisition unit and will be copied into the milling of the porcelain. This design mode is indicated if the preoperative condition of the tooth has adequate occlusal anatomy, or if a “mock-up” of a broken tooth has been done. Cusp shapes and heights, marginal ridge heights, and some buccal and lingual anatomy are copied into the restoration well enough that seldom are more than very minimal adjustments needed.

A shallow, fairly conservative amalgam was removed with a new 330 bur and the tooth was examined (Figure 19). From the occlusal view a mesiodistal crack was not obvious. Sable Seek^u caries indicator was applied. After checking twice with the caries indicator, all old restorative material and caries were removed, making

^uUltradent, South Jordan, UT 84095; (800) 552-5512

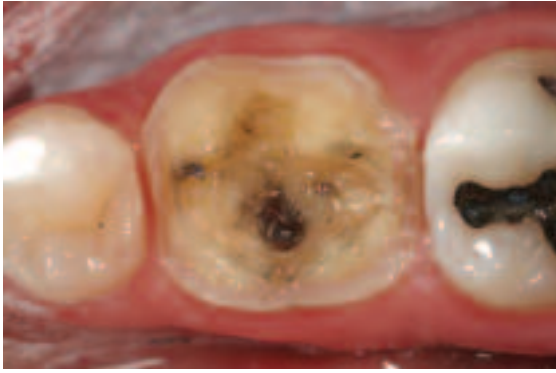

Figure 19—The preparation focuses on removing all old filling material, bases, and liners, and covers any obvious tooth cracks.

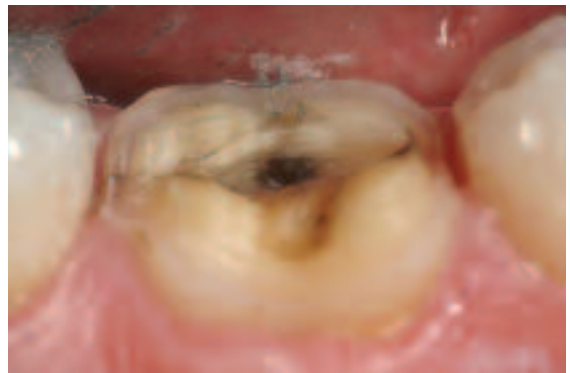

Figure 20—A preparation with 2 mm clearance and all decay and filling material removed. Note the fracture running from the mesial to the distal through the lingual cusps.

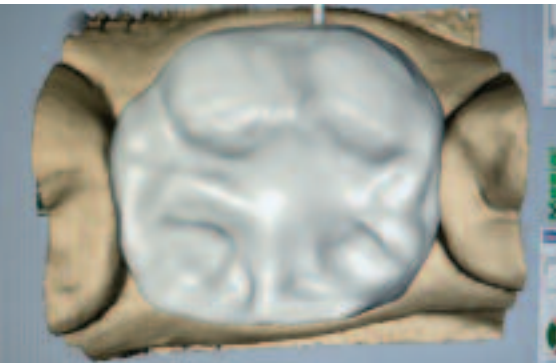

Figure 21—The preoperative anatomy of the tooth was copied into the restoration in the Cerec "Correlation" mode and slightly enhanced by the operator.

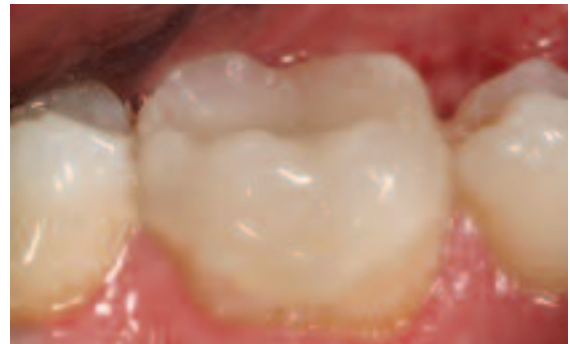

Figure 22—The restoration was etched, silanated, bonded, and luted into place with a resin build-up material. The occlusion was then checked and adjusted, and the restoration polished.

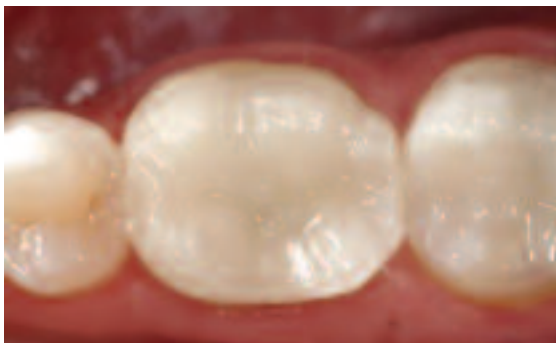

Figure 23—At recall appointment of over 2 years, no sensitivity was reported and the patient remained symptom-free.

the crack more evident. It ran from mesial to distal under the lingual cusps when looking from the buccal (Figure 20).

The preparation was completed with definite rounded shoulder margins, rounded internal corners, and a minimum of 2 mm excursive clearance.

Treatment

The tooth was powdered and the image acquired with the Cerec 3. The restoration was designed and milled in about 20 minutes in the

"correlation" mode (Figure 21). In this case, Pro-CAD^b porcelain, a leucite-reinforced porcelain with characteristics similar to Empress,¹⁹ was used. The porcelain was etched with hydrofluoric acid for 2 minutes, and silane coupler was applied and dried in 10 seconds. Then a bonding agent was applied, air thinned, and cured as described in Case 1. The restoration was cemented with Build-It FR, adjusted, and polished as described above (Figure 22). The patient was happy to again be able to eat without discomfort and reported no further sensitivity at each recall examination over a 2 year period (Figure 23).

Conclusion

Every practitioner should be aware of the existence of CTS and the myriad of diagnostic and treatment alternatives for symptomatic teeth. Nothing can replace listening to the patient's history, thoroughness of clinical examination, or experience of the practitioner. All are equally important to achieving a successful outcome.

Once pulpal and periodontal disease are

ruled out or treated, patients with biting sensitivity can be methodically checked by loading each cusp and fossa to determine painful areas of each tooth. Many of these teeth can be successfully treated with conservative, bonded porcelain restorations that remove or cover only those parts of the tooth deemed to be causing the symptoms. Most dental practitioners can confidently manage these patients with definitive, successful treatment.

Disclosure

Jack D Griffin, Jr DMD FAGD has no financial interest in any way with the products, materials, or suppliers used in this article.

References

- Lynch CD, McConnell RJ. The cracked tooth syndrome. *J Can Dent Assoc.* 2002;68:470-475.
- Thomas GA. The diagnosis and treatment of the cracked tooth syndrome. *Aust Prosthodont J.* 1989;3:63-67.
- Turp JC, Gobetti JP. The cracked tooth syndrome: an elusive diagnosis. *J Am Dent Assoc.* 1996;127:1502-1507.
- Cohen S, Burns RC. *Pathways of the Pulp.* Mosby Year Book. 8th ed.
- Cracking the cracked tooth code. *Endodontics – Colleagues for Excellence: American Association of Endodontist newsletter,* fall/winter 1997.
- Geurtsen W, Schwarze T, Gunay H. Diagnosis, therapy, and prevention of the cracked tooth syndrome. *Quintessence Int.* 2003;34:409-417.
- Mounce R. Endodontic diagnosis for vital inflamed cases. *Compend Contin Educ Dent.* 2004;25:86-92.
- Walton RE, Torabinejad M. *Principles and Practice of Endodontics.* Saunders; 1996.
- Clinical Research Associates. Products highly rated by CRA evaluators in clinical field trials. *CRA Newsletter.* 1995;18:1-4.
- Cohen S, Burns RC. *Pathways of the Pulp.* Mosby Year Book, 5th ed. 1995.
- Opdam NJ, Roeters JM. The effectiveness of bonded composite restorations in the treatment of painful, cracked teeth: six-month clinical evaluation. *Oper Dent.* 2003;28:327-333.
- Cerec Symposium 2001. *Compend Contin Educ Dent (suppl).* 2001;22.
- Martin N, Jedyankiewicz NM. Clinical performance of CEREC ceramic inlays: a systematic review. *Dent Mater.* 1999;15:54-61.
- Hiatt WH. Incomplete crown root fracture in pulpal periodontal disease. *J Periodontol.* 1973;44:369-379.
- Fasbinder DJ. Restorative material options for CAD/CAM restorations. *Compend Contin Educ Dent.* 2002;23:911-922.
- Reality 2004 Buyer's Guide* Reality Publishing Company. 2004;18:241-299.
- Jain R, Reinhardt JW, Krell DV. Effect of dentin desensitizers and dentin bonding agents on dentin permeability. *Am J Dent.* 2000;13:21-27.
- Kanka J, Suh BI. Pulse activation: reducing resin-based composite contraction stresses at the enamel cavosurface margins. *Am J Dent.* 1999;12:107-112.
- Gaglio MA. Esthetic restorations designed with confidence and predictability. *Compend Contin Educ Dent (suppl).* 2001;22:30-34.

Quiz 2

1. **No treatment can succeed if:**
 - a. the patient does not watch an educational DVD.
 - b. a CAD/CAM machine is not used.
 - c. the diagnosis is incorrect.
 - d. complete and full coronal coverage is not performed.
2. **Irreversible pulpitis is indicated and endodontic treatment should be considered if:**
 - a. radiographic examination indicates a periapical lesion.
 - b. there is lingering cold sensitivity
 - c. there is heat-induced pain, throbbing, or spontaneous pain.
 - d. all of the above
3. **The Tooth Slooth^a is a 2-ended instrument with a dimpled concave end that is placed:**
 - a. on cusp tips after the patient bites.
 - b. in the central fossa.
 - c. on the buccal surface after the patient bites.
 - d. directly on cusp tips.
4. **The goal of treatment is to:**
 - a. drill away all large fractures and craze lines.
 - b. immobilize the segments of the tooth that move on loading.
 - c. achieve 360° of coverage so that all fractures, craze lines, and potential pathology are fully covered.
 - d. apply desensitizer to the prepped tooth to alleviate pain.
5. **Because of the trend in dentistry to preserve tooth structure:**
 - a. patient fees are kept as low as possible.
 - b. single appointment porcelain fabrications and cementation can be successful.
 - c. preparation time is kept to a minimum.
 - d. Cerec milling time is reduced.
6. **The Cerec system:**
 - a. completes the restoration in 1 visit without fabrication and maintenance of less-than-ideal-fitting temporaries.
 - b. lessens the chance of bacterial invasion from microleakage along the fracture.
 - c. reduces tooth manipulation from a second appointment.
 - d. all of the above
7. **Reasons why non-etch bonding systems may decrease iatrogenic sensitivity include:**
 - a. dentinal smear layer left unviolated
 - b. dentinal tubules are never unsealed
 - c. less chance of gingival bleeding from caustic phosphoric acid, so less chance of contaminated margins
 - d. all of the above
8. **The sonic vibration helps to:**
 - a. ensure complete seating of the restoration.
 - b. reduce the chances of voids in the luting agent.
 - c. decrease the chances of voids under the restoration.
 - d. all of the above
9. **The curing light is turned on by the assistant and handed to the dentist, and then the tooth is approached slowly to:**
 - a. reduce negative polymerization forces and reduce white lines near the margins.
 - b. decrease heat buildup in the tooth.
 - c. cause the luting composite to shrink toward the curing light.
 - d. provide ample time for porcelain finishing.
10. **In Case 2, the porcelain was:**
 - a. wiped with alcohol.
 - b. coated with cyanoacrylate.
 - c. placed in an ultrasonic cleaner on high.
 - d. etched with hydrofluoric acid, and silane coupler was applied.

Please see tester form on page 36.

This article provides 1 hour of CE credit from Ascend Media's Dental Learning Systems, in association with the University of Southern California School of Dentistry and the University of Pennsylvania School of Dental Medicine, representatives of which have reviewed the articles in this issue for acceptance. Record your answers on the enclosed answer sheet or submit them on a separate sheet of paper. You may also phone your answers in to (888) 596-4605 or fax them to (703) 404-1801. Be sure to include your name, address, telephone number, and social security number.