

Immediate Definitive CAD/CAM Restoration of a Non-submerged Implant

CE 1

Abstract: *Implant placement has become a widely accepted treatment for tooth replacement. There are many restorative options, but it is best for the patient and most efficient for the office if the implant is placed and restored in as few appointments as possible. If diagnosis is thorough and accurate, placing the implant and doing a definitive restoration in 1 appointment can be as predictable as the traditional 2 appointment technique. Restoring the implant with computer-assisted designed and machined porcelain can provide predictable fit, esthetics, and restoration and be clinically efficient.*

Jack D Griffin, Jr, DMD, FAGD
Private Practice
Eureka, Missouri

Contemporary dentistry offers many choices for posterior single-tooth replacement. Implants offer the chance to replace missing teeth without preparing neighboring teeth, without the chance for recurrent decay, without periodontal stresses placed on adjacent teeth, and without much fee difference from traditional bridge work. The current success of dental implants cannot be denied if the patients are chosen correctly, the treatment plan is done thoroughly, the surgery is done skillfully, and the restoration is designed properly.

While implants have a fairly long and studied history, there are varied opinions on surgical techniques and restoration design. Traditionally, implants have been placed, submerged under soft tissue for 3 to 6 months, and allowed to integrate into the alveolar bone without the stress of loading to promote osseointegration.^{1,2}

Immediate loading of implants without the more traditional soft-tissue submersion and lengthy integration has garnered more support in the literature and with many practitioners recently.³ However, many of these studies were done using transitional composite or acrylic temporary prostheses and not with definitive long-term restorations.^{4,6}

In the following case a root form implant was placed and restored with a CAD/CAM all-porcelain crown in a single visit. The patient selection, surgery, and restorative procedures were combined for efficiency and predictability. These methods often can be used for single tooth replacement.

Patient History

A long-time patient presented for immediate implant placement after having tooth No. 20 removed 9 months earlier because of failed endodontic treatment as the result of a vertical root fracture. The tooth was moved without removing bone and the extraction site was well healed (Figure 1). A lingual tori was continuous from tooth No. 19 through No. 22. The patient had a lengthy dental history with multiple crowns and fillings and was "excited" by the opportunity to replace the tooth without manipulation of adjacent teeth.

No obvious parafunctional habits existed and there was no history of broken teeth or restorations during many years in this practice. The patient's oral hygiene and dental knowledge also were very good and

Learning Objectives:

After reading this article, the reader should be able to:

- describe requirements that would lead to success with immediate implant placement and loading.
- describe important surgical considerations to increase the survival of immediate implant restoration.
- discuss advantages in the single appointment fabrication of computer-assisted designed and machined porcelain for implant restoration.
- explain why porcelain placed on a metal implant abutment should be stained and glazed.

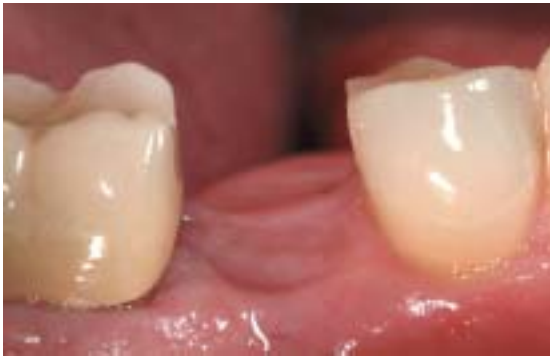

Figure 1—Preoperative condition of the healthy extraction site with good attached tissue.

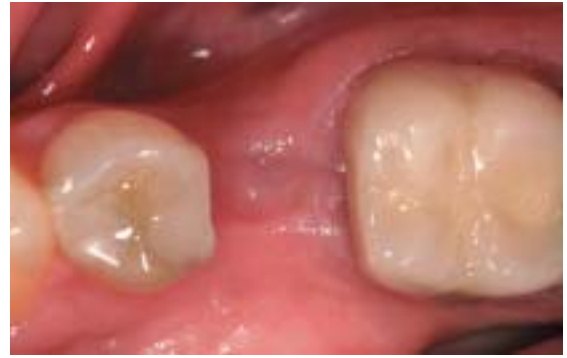

Figure 2—Sufficient bone width exists and presence of a lingual tori.

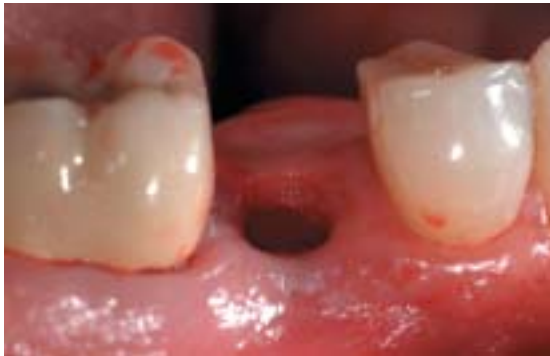

Figure 3—Osteotomy was completed using a sequence of drills with no gingival flap.

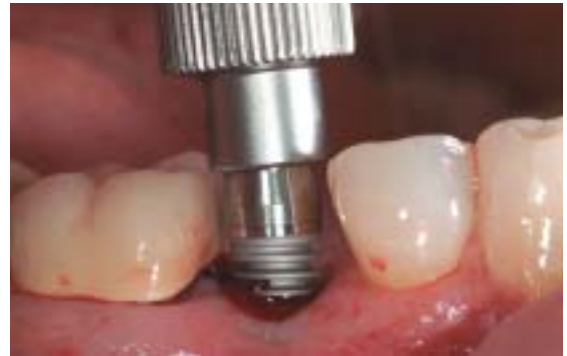

Figure 4—Initial placement of the 5 mm x 12 mm implant with a finger wrench, which was followed by a ratchet to ensure complete, nontraumatic seating.

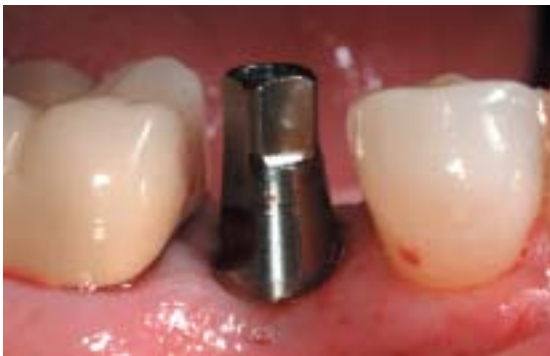

Figure 5—Complete seating was done using the implant abutment that came with the implant. The antirotational bevel is at 45° toward the molar.

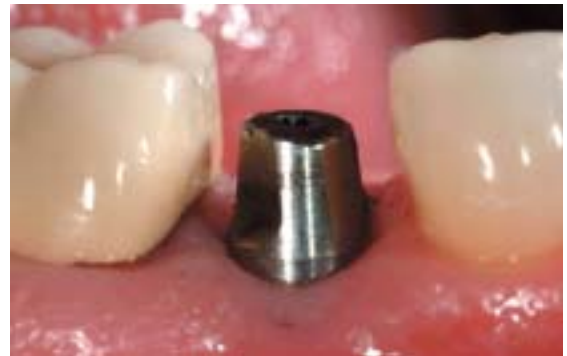

Figure 6—The abutment was reduced occlusally with a high-speed handpiece and copious water to leave 3 mm of clearance in all mandibular movements. The corners were rounded so stress points would not be created within the porcelain restoration.

regular maintenance appointments were kept. He was a nonsmoker and had no medical history or medications that would compromise the immune system healing. Radiographs revealed a well healed extraction site.

Treatment Plan

After clinical and radiographic examination it was determined that sufficient bone was available for a 5 mm diameter implant. There was 10 mm of space from the mesial of the first molar to the distal of the second bicuspid and ample interproximal width to place and restore the implant (Figure 2). There was ample

attached gingiva around the proposed implant site and healthy contours.

Several implant systems could work within the parameters of this case, including Screw-Vent internal hex implants^a and Nobel/Brånemark screw implants^b. A myriad of esthetic porcelain systems also have been used for the definitive prosthesis, including reinforced all-porcelain crowns such as Finesse^c, Procera^b, and In-Ceram^d.

It was decided in this case to place a 5 mm

^aCenterpulse Dental Inc, Encino, CA 92882 (800) 598-3029

^bNobel Biocare, Yorba Linda, CA 92887 (800) 993-8100

^cDentsply/Ceramco Burlington, NJ 08016 (800) 487-0100

^dVident, Brea, CA 92821; (714) 961-6200

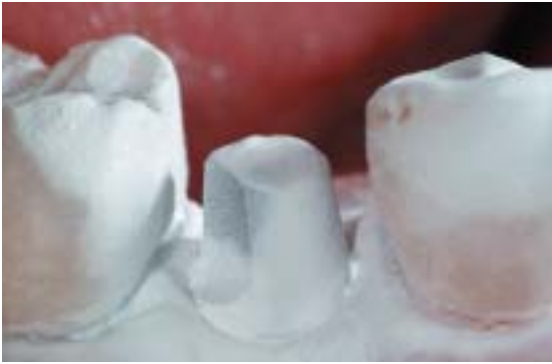

Figure 7—The surface of the gingiva, the abutment, and the adjacent teeth were powdered with titanium dioxide to provide a reflective surface for the CEREC acquisition unit.




Figure 8—Once scanned into the CEREC 3 machine, the restoration can be made.



Figure 9—After the die is trimmed, the margin and gingival periphery of the restoration are traced about 2 mm onto the gingiva and not on the abutment itself.

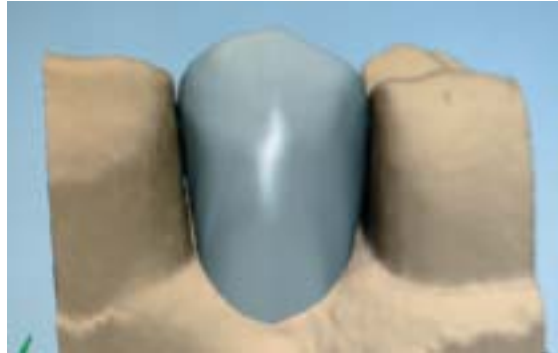


Figure 10—The CEREC proposal before editing.



Figure 11—Looking from the gingival aspect of the restoration shows clearly the incorporation of the antirotational bevel. The restoration will be fabricated with slight gingival contact as shown in tan around the abutment.

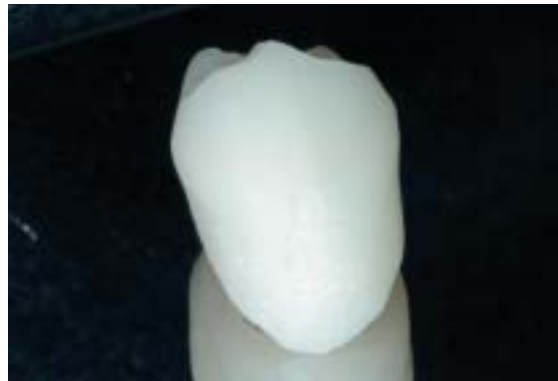

Figure 12—Milled in about 14 minutes, the restoration has a roughened surface that is ready to try in.

× 12 mm Maestro[®] D2 implant and restore with a ProCAD^f porcelain CEREC^g restoration in a single visit. Because of the need for high implant stability when immediately loading, the design of the implant is critical. Maestro implants can be easily restored, the surgical protocol is simple, and the implants are designed with a thread feature that increases surface area for effective osseointegration.⁷

The implants are labeled according to bone

⁷Biohorizons, Birmingham, AL 35243; (888) 246-8338

^fIvoclar Vivadent, Inc, Amherst, NY 14228; (800) 552-5512

^gSirona USA, Charlotte, NC 28273; (800) 659-5977

density types to help the practitioner choose an implant that suits the bone they are being placed into. In this case, a “D2” implant was chosen because of the porous cortical and coarse trabecular bone in the bicuspid area of the mandible. This implant has been roughened by sandblasting with soluble particles, a “Resorbable Blast Media” finish, to increase surface area and provide more implant surface area onto which bone can integrate.⁸ These design features make this system particularly suitable for immediate nonfunctional loading.⁹

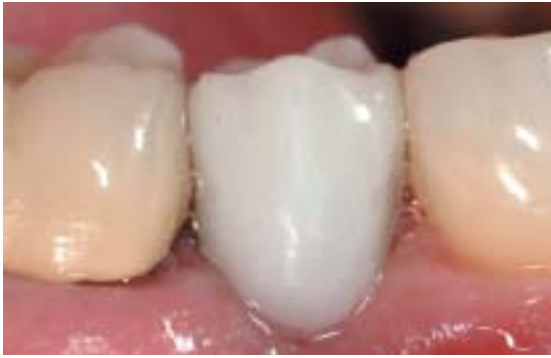

Figure 13—With the first try-in and no adjustment other than sprue removal, the contacts and fit are verified. The occlusion in centric and all excursive movements are checked to ensure the restoration is just out of occlusion.

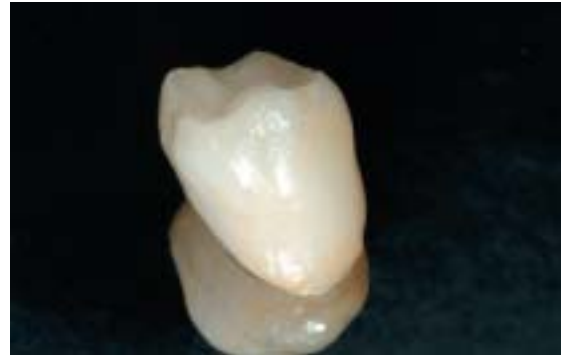

Figure 14—A one bake staining and glazing was completed. After cooling, the restoration was porcelain etched and silanated and ready for cementation.

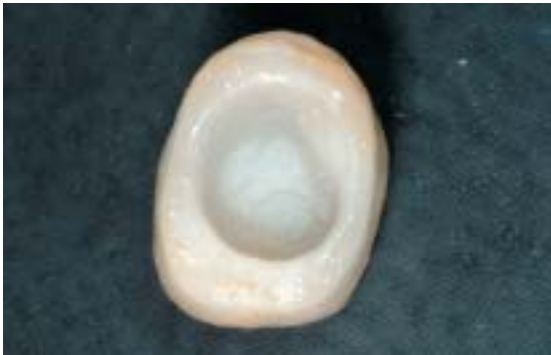

Figure 15—The porcelain that will slightly touch the gingiva is glazed to reduce the chances of plaque accumulation.

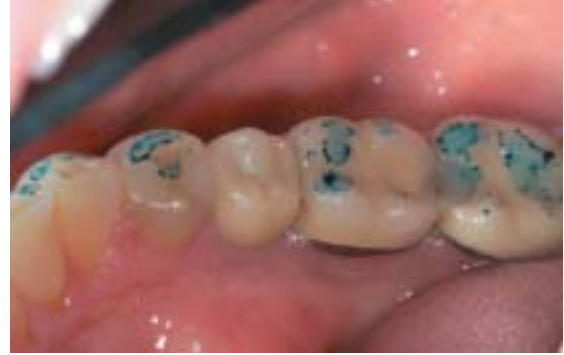

Figure 16—The occlusion is checked for a second time to ensure no functional or parafunctional contacts are made. The tooth is less than 0.5 mm out of occlusion.

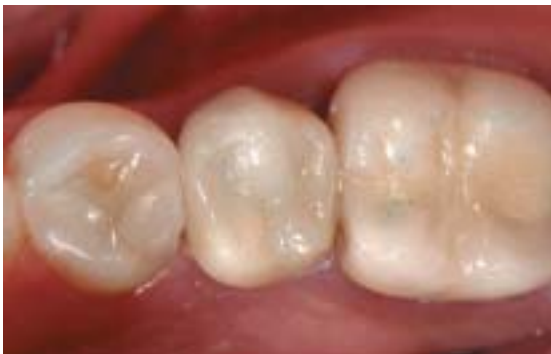

Figure 17—After cementation, the occlusion is verified a third time.

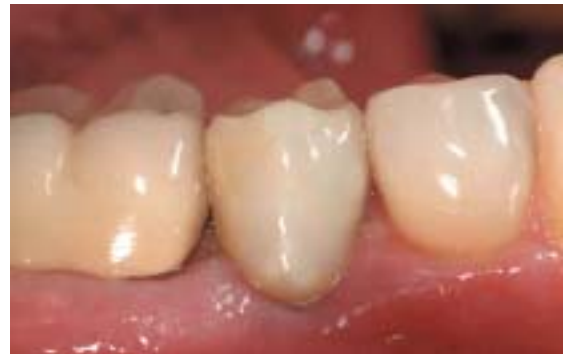

Figure 18—After cement clean up, tissues are checked to ensure there is no blanching of the gingiva including the papillae.

Immediate Nonfunctional Loading

Over the past 15 to 20 years there has been much studied and written about 1 stage or nonsubmerged implant procedures.¹⁰ There have been several studies and many articles describing the success of immediate loading of implants as long as careful preoperative evaluation and treatment planning are considered.¹¹ A second uncovering appointment is not needed because a provisional tooth is normally placed at the surgical appointment. The patient is spared the emotional and physical trauma of a second surgical appointment and

the practitioner provides the implant service more efficiently for the practice.

Certain requirements must be met for the loading of an implant at the time of surgery (Table 1). We want to control the amount of micromovement of the implant, which is controlled by bone quality, occlusion, surgical technique, and implant design.¹² During implant placement, we want to use sharp sequential drills that induce as little heat, vibration, and bone trauma as possible. If bone anatomy can be visualized so that proper implant positioning can occur without laying a flap, the lack of an inci-

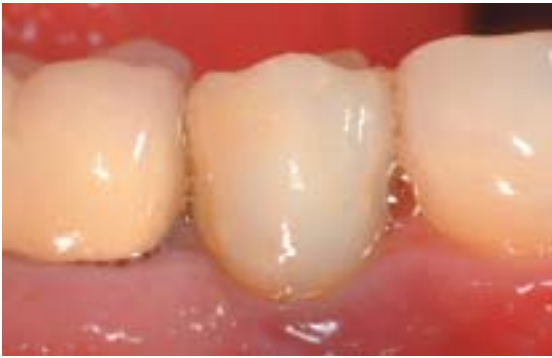

Figure 19—At a 1 year prophy appointment, the patient is functioning well and all tissues appear healthy.

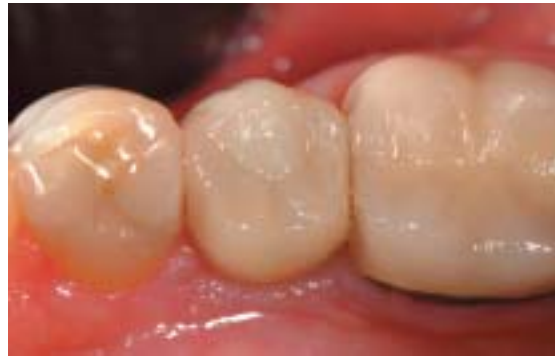

Figure 20—Restoration at 1 year with acceptable esthetics and anatomy.

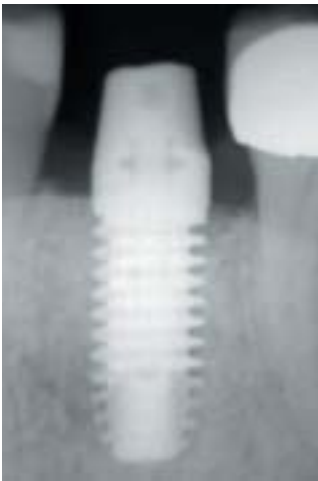


Figure 21—Radiograph at 1 year with restoration removed. Bone loss down to the first thread with radiographic integration.

sion can be advantageous because there will be less chance of tissue trauma and bacterial invasion from the healing incision and suture placement.

The more implant stability the more predictable the outcome. The well healed bone density in the posterior mandible provides the opportunity for a careful, atraumatic osteotomy and implant placement. The osteotomy needs to be done with sharp, concentric, well-designed drills with careful speed, pressure, and irrigation to control heat and bone preparation size.

The construction of a computer-assisted design/computer-assisted machined (CAD/CAM) restoration at the surgical appointment will allow the practitioner to have complete control over occlusion, contacts, and adaptation of the restoration around the implant. Besides the osteotomy, solid contacts of the restoration with adjacent teeth and the control of functional and nonfunctional occlusion can help reduce the implant micromovement, which may increase implant success. The ability to control these factors reduces the errors that may develop

in communication between the surgeon, restoring dentist, and the lab.

Surgical Procedure

In this case, buccal and lingual infiltration was done with articaine. This provided sufficient anesthetic so the patient was comfortable during the procedure, but allowed for some positive sensation should the osteotomy approach the mandibular nerve. The placement was begun at the midpoint in the edentulous area and parallel to the imaginary line bisecting the neighboring roots. This left about 3 mm mesial and distal between the implant and the adjacent teeth.

No flap was made and the osteotomy was begun by drilling a pilot hole with a #6 round bur followed by a sequence of drills from 2.0 mm to 4.2 mm, as recommended by the manufacturer's surgical manual, parallel to the roots of the adjacent teeth and perpendicular to the cortical plate at the placement point (Figure 3). A crestal bone drill of 5 mm diameter was then used only on the cortical plate of bone so the alveolus would readily and atraumatically accept the implant.

Because the pilot drill was taken through the soft tissue, it was prudent to ensure a clean osteotomy so that no soft tissue was included as the implant was placed. Copious rinsing along with visual inspection was done. This helped ensure that epithelium was not inadvertently taken into the osteotomy, which could have the potential to form a nonosseous epithelial interface between the alveolus and the implant.

The 5 mm implant was then initially placed with a hand wrench and finished with a ratchet and extender (Figure 4). The implant was seated completely with the top of the implant at the height of the cortical plate and

Table 1—Requirements for Immediate Implant Loading

1. Quality bone
2. Minimally traumatic surgery
3. The absence of infection
4. High immediate implant stability
5. Controlled and minimized occlusal loads
6. Meticulous plaque control

Table 2—Advantages of CAD/CAM CEREC Restorations for Implant Crown

1. Efficient design and fabrication
2. Reduced implant component inventory
3. No need for temporary fabrication or problems
4. No heat build up on abutments
5. Excellent adaptation of porcelain to abutment
6. Occlusion easily adjusted in mouth before glazing
7. Tissue contact surfaces can be glazed
8. Adjacent tooth contacts ideally controlled
9. Wear similar to natural teeth

Table 3—Keys to Blocking Out Metal Abutment with All-porcelain Restorations

1. Porcelain with sufficient opacity
2. Ample thickness of porcelain
3. Ability to be stained
4. Use of opaque luting agent

only the abutment was visible above the tissue (Figure 5). To increase “osseoadaptation,” care was taken to rotate the implant into the socket with as little buccal-lingual or mesio-distal movement as possible while ensuring a complete and tight fit into the osteotomy. For success, keep the fit of the implant as tight as possible with as much direct contact with bone as possible.

CAD/CAM CEREC Restorations

CEREC CAD/CAM porcelain restorations have had over 20 years of scrutiny by the dental community and have proven to be reliable,

cost effective, and often very esthetic restorations.¹³ Indirect CAD/CAM single-visit restorations have been very successful restorations for many years now and have withstood rigorous scrutiny.¹⁴ No other direct single visit porcelain fabrication option exists today unless there is an in-office porcelain laboratory. Impressions could be taken, poured up, and an in-house lab could fabricate the restoration in a single visit; however, office efficiency suffers.

Single visit CAD/CAM porcelain restorations for an immediate implant prosthesis can provide benefits that could increase the chances of clinical success with immediate implant loading (Table 2). [Author: “entertain plaque” correct?] There is no tissue manipulation for an impression, no heat buildup that could be transferred to the bone by the implant abutment from temporary formation, and no temporary placement that may entertain plaque more than a glazed porcelain restoration.

There are 3 main choices for CEREC porcelain: Vita Mark II^h, ProCAD, and Paradigm MZ100ⁱ. Each has its own nuances and advantages. Vita and ProCAD are porcelains with similar milling, polishing, and handling characteristics and both can be stained and glazed with the necessary strength to be used for full all-porcelain coverage. ProCAD is very similar in characteristics to IPS Empress^g with similar wear to enamel.¹⁵ It is an esthetically acceptable porcelain that can be stained and glazed to match other teeth and to block out abutment color (Table 3). Paradigm is an MZ100 composite with excellent wear and esthetics, but because it is a composite, it is less likely to hold a high shine compared with glazed porcelain and may not control plaque efficiently.¹⁶

Restorative Procedure

The Maestro system used in this case comes with a screw-retained prosthetic abutment and has a beveled side that provides an antirotational feature for the prosthesis. The abutment was shortened with a football diamond on a high-speed handpiece using copious water. Care must be taken to prevent heat buildup on the abutment, which may be transferred to bone, compromising osseointegration (Figure

^hVita Zahnfabrik, Germany, distributed in US by Patterson, St Paul, MN 55120; (800) 325-3184

ⁱ3M, St Paul, MN 55144; (800) 634-2249

6). The corners were rounded and smoothed with a finishing bur to reduce sharp angles, which can lead to stress points and porcelain fractures.

A glycerin-based adhesive liquid was applied to the tooth followed by a titanium dioxide reflective medium. This powder is blown onto the tooth using a specialized sprayer that connects to the operatory compressed air system. Care is taken to completely cover the implant abutment, gingiva, and adjacent teeth so that the CEREC acquisition unit can capture as much data as possible for porcelain design efficiency (Figure 7). The image of the abutment was captured using the CEREC acquisition unit (Figure 8). After trimming the dye, the margins were traced 2 mm onto the tissue that surrounded the implant abutment (Figure 9). This allowed for sufficient thickness of porcelain for strength and for abutment color block out. This design also provided an excellent emergence profile for esthetics.

The CEREC system has several program design options. In this case, the dental database mode was used. This mode uses a tooth shape and size database within the computer according to the surrounding teeth and anatomy to propose a tooth form. Within this design mode, the optional proposal from lab technician Lee Culp was selected and the proposed crown was inspected (Figure 10). Alterations were made in the proposal height and the contact position and strength by using the scale tool. The complete design was finished in about 4 minutes. Because of the excellent adaptation of the porcelain in this system, the antirotational bevel was successfully incorporated into the restoration (Figure 11).

The milling in this case took about 14 minutes (Figure 12). It was tried in with no adjustment to inspect adaptation, anatomy, and fit (Figure 13). With this design, it is desirable to have tissue contact when fully seating but no blanching that may cause tissue stress. After fine-tuning contacts and anatomy, the occlusion was checked in all lateral and functional movements to ensure the restoration was very slightly out of occlusion. Porcelain shade 100 was used, an intentionally high color value shade that was altered with staining.

ProCAD stain and glazing medium was applied. It was heated and held 1 minute at

950° F without vacuum in a Ivoclar Programat P100g oven. The total time with cooling was about 20 minutes (Figure 14). It is very important to glaze the porcelain that will come in contact with the soft tissues, making plaque accumulation difficult (Figure 15). In this case, the design called for direct contact of the glazed porcelain with the gingiva to reduce tissue stress. This created a smoother and more hygienic tissue-friendly environment.

The occlusion was rechecked thoroughly to ensure there were no functional or para-functional occlusal contacts (Figure 16). Anatomy, contours, and soft-tissue fit were evaluated before cementation (Figure 17). The porcelain was etched with hydrofluoric acid for 2 minutes, silane coupler applied for 10 seconds, and dried. The hex screw hole was blocked out with wax. The crown was cemented with a dual-cure luting composite without using any bonding agents (Figure 18). This allowed, if necessary, for removal at recall appointments with a crown remover.

At 1 year, the fit, color, and tissue adaptation are excellent (Figures 19 and 20). A crown remover was used to tap the restoration from the implant post, and tissue response was excellent. A radiograph after porcelain removal showed good bone adaptation and healing (Figure 21). The porcelain was then recemented with the same non-bonding luting technique as before. The patient reported a “terrific experience.”

Conclusion

In this case the implant was placed and the restoration milled, fitted, glazed, and cemented in about 90 minutes. Patient acceptance for this treatment should increase because surgical manipulation is limited to 1 appointment. Dentist acceptance should increase because office efficiency is maximized and clinical success is as predictable as traditional 2-stage implant placement.

Immediate nonfunctional implant restorations are now considered a viable option for many practitioners now. Future study and research will be needed to make this technique more accepted by the profession and should show that longevity meets or exceeds traditional implant placement and restoration and conventional crown and bridge procedures.

Disclosure

Jack D Griffin, Jr DMD, has no financial interest with the products, materials, or suppliers discussed in this article.

References

1. Branemark PI, Hansson BO, Adell R, et al. Osseointegrated implants in the treatment of the edentulous jaw. Experience from a 10-year period. *Scand J Reconstr Surg.* 1977;11:1-132.
2. Adell R, Lekholm U, Rockler B, et al. A 15 year study of osseointegrated implants in the treatment of the edentulous jaw. *Int J Oral Surg.* 1981;10:387-416.
3. Degidi M, Piatelli A. Immediate functional and non-functional loading of dental implants: a 2- to 60-month follow-up study of 646 titanium implants. *J Periodontol.* 2003;74:225-241.
4. Wöhrle P. Immediate implant placement and provisionalization: 3-5 years statistical results. *Acad Osseint.* 2000;3:9-11. [Author: Please verify ref. 4]
5. Randow K, Ericsson I, Nilner K, et al. Immediate functional loading of Branemark dental implants. An 18 month clinical follow-up study. *Clin Oral Implants Res.* 1999;10:8-15.
6. Cooper L, Felton DA, Kugelberg CF, et al. A multicenter 12-month evaluation of single tooth implants restored 3 weeks after 1-stage surgery. *Int J Oral Maxillofac Implants.* 2001;16:182-192.
7. Strong JT, Misch CE, Bidez MW, et al. Functional surface area: thread-form parameter optimization for implant body design. *Compend Contin Educ Dent.* 1998;19(special issue):4-9.
8. Novaes AB Jr, Souza SL, de Oliveira PT, et al. Histomorphometric analysis of the bone-implant contact obtained with 4 different implant surface treatments placed side by side in the dog mandible. *Int J Oral Maxillofac Implants.* 2002;17:377-383.
9. Mish CE. Non-functional immediate teeth in partially edentulous patients: a pilot study of 10 consecutive cases using the Maestro Dental Implant System. *Compend Contin Educ Dent.* 1998;19(special issue):4-9,25-36.
10. Misch CE, Degidi M. Five-year prospective study of immediate/early loading of fixed prostheses in completely edentulous jaws with a bone quality-based implant system. *Clin Implant Dent Relat Res.* 2003;5:17-28.
11. Saadoun AP, Sebbag P. Immediate implant placement and temporization: literature review and case studies. *Compend of Contin Educ Dent.* 2004;25:277-296.
12. Aparicio C. Our hopes for the Barcelona consensus [editorial]. *Clin Implant Dent Relat Res.* 2003;5:1-2.
13. Reiss B. Long-term clinical performance of CEREC restorations and the variables affecting treatment success. *Compend of Contin Educ Dent.* 2001;22:14-18.
14. Martin N, Jedyankiewicz NM. Clinical performance of CEREC ceramic inlays: a systematic review. *Dent Mater.* 1999;15:54-61.
15. Gaglio MA. Esthetic restorations designed with confidence and predictability. *Compend Contin Educ Dent.* 2001;22(suppl):30-34.
16. Rusin RP. Properties and applications of a new composite block for CAD/CAM. *Compend of Contin Educ Dent.* 2001;22:35-41.

Quiz 1

- Traditionally, implants have been:**
 - submerged.
 - placed under soft tissue for 3 to 6 months.
 - allowed to integrate into the alveolar bone without the stress of loading.
 - all of the above
- In this case, the bone in the bicuspid area of the mandible can be best described as:**
 - porous cortical and coarse trabecular bone.
 - nondense trabecular bone.
 - soft, porous bone.
 - a poor choice for dental implants.
- The implant was roughened by sandblasting with soluble particles, "Resorbable Blast Media"¹¹ finish, because:**
 - it makes complete insertion more likely.
 - the finish increases surface area, which provides more implant into which bone can integrate.
 - it allows a better fit of the prosthesis.
 - it allows better adaptation of the CEREC titanium dioxide powder.
- What requirements must be met for loading of an implant at the time of surgery?**
 - control the amount of micromovement of the implant
 - minimally traumatic surgery for 2 stage procedures only
 - high immediate implant stability for implants at least 6 mm in diameter
 - final coronal restoration must be completed simultaneously
- During implant placement, use sharp sequential drills that induce as little of which of the following as possible?**
 - heat
 - vibration
 - bone trauma
 - all of the above
- The lack of an incision can be advantageous because there is less chance of:**
 - tissue trauma and bacterial invasion from the healing incision.
 - periimplant tissue sloughing.
 - periimplantitis as a result of the supragingival margin.
 - periimplantitis as a result of the periapical margin.
- The Maestro system used in this case comes with what type of abutment?**
 - screw-retained
 - pin-retained
 - semirotational
 - subgingival post preparation
- Care must be taken to prevent what on the abutment, which may be transferred to bone?**
 - long impression copings
 - heat build up
 - impression material
 - excessive cord placement forces
- After trimming the dye, the margins were traced how far onto the tissue that surrounded the implant abutment?**
 - 0.5 mm
 - 0.05 mm
 - 2 mm
 - 4 mm
- In this case, the implant was placed, the restoration milled, fitted, glazed, and cemented in about:**
 - 15 minutes.
 - 45 minutes.
 - 90 minutes.
 - 2 days.

Please see tester form on page xxx.

This article provides 1 hour of CE credit from Dental Learning Systems, in association with the University of Southern California School of Dentistry and the University of Pennsylvania School of Dental Medicine, representatives of which have reviewed the articles in this issue for acceptance. Record your answers on the enclosed answer sheet or submit them on a separate sheet of paper. You may also phone your answers in to (888) 596-4605 or fax them to (703) 404-1801. Be sure to include your name, address, telephone number, and social security number.